A 4-year-old Caucasian boy is evaluated for difficulty walking. Past medical history includes frequent respiratory infections. Cultured cells from this patient demonstrate a high rate of radiation-induced genetic mutation. This patient is most likely to experience which of the following?

A. Neurofibrillary tangles in neocortex

B. Cerebellar atrophy

C. Loss of neurons in the substantia nigra

D. Atrophy of caudate nucleus

E. Posterior column degeneration

F. Presence of Lewy bodies

Submit

A 4-year-old Caucasian boy is evaluated for difficulty walking. Past medical history includes frequent respiratory infections. Cultured cells from this patient demonstrate a high rate of radiation-induced genetic mutation. This patient is most likely to experience which of the following?

- A. Neurofibrillary tangles in neocortex (5%)
- ✓ B. Cerebellar atrophy (56%)
- C. Loss of neurons in the substantia nigra (3%)
- D. Atrophy of caudate nucleus (6%)
- E. Posterior column degeneration (24%)
- F. Presence of Lewy bodies (4%)

Omitted
Correct answer
B

56%
Answered correctly

03 secs
Time Spent

02/03/2020
Last Updated

Explanation

Ataxia-telangiectasia is an autosomal recessive disorder. Cerebellar atrophy leads to the **ataxia** that occurs in the first years of life. (**Oculocutaneous telangiectasia** is another manifestation, but is usually delayed. Telangiectasias are abnormal dilatations of capillary vessels.) Patients with ataxia-telangiectasia also have severe immunodeficiency with **repeated sinopulmonary infections**. The risk of **cancer** in these patients is increased significantly because of inefficient DNA repair.

DNA damage and repair is an ongoing process. A lot of naturally-occurring agents cause DNA damage: sunlight, UV light, ionizing radiation

Ataxia-telangiectasia is an autosomal recessive disorder. Cerebellar atrophy leads to the **ataxia** that occurs in the first years of life. (**Oculocutaneous telangiectasia** is another manifestation, but is usually delayed. Telangiectasias are abnormal dilatations of capillary vessels.) Patients with ataxia-telangiectasia also have severe immunodeficiency with **repeated sinopulmonary infections**. The risk of **cancer** in these patients is increased significantly because of inefficient DNA repair.

DNA damage and repair is an ongoing process. A lot of naturally-occurring agents cause DNA damage: sunlight, UV light, ionizing radiation (gamma and X-ray), and free oxygen radicals are produced during the cell cycle. Some chemicals (hydrocarbons in cigarette smoke, aflatoxins produced by moldy peanuts) are also harmful to DNA. DNA repair occurs continuously by means of direct reversal of damage, base and nucleotide excision repair, and mismatch repair.

A number of inherited disorders are caused by deficient DNA-repair enzymes:

1. Ataxia-telangiectasia is characterized by DNA hypersensitivity to ionizing radiation.
2. In xeroderma pigmentosum, DNA is hypersensitive to UV radiation, causing premature skin aging and increased risk of skin cancer (malignant melanoma and squamous cell carcinoma).
3. Fanconi anemia is caused by hypersensitivity of DNA to cross-linking agents.
4. Bloom syndrome is characterized by generalized chromosomal instability. Increased susceptibility to neoplasms is present.
5. Hereditary nonpolyposis colorectal cancer (HNPCC) occurs due to a defect in DNA mismatch-repair enzymes. It leads to increased susceptibility to colon cancer.

(Choice A) Neurofibrillary tangles in the neocortex are seen in Alzheimer disease.

(Choice C) Loss of neurons in the substantia nigra is characteristic of Parkinson disease.

(Choice D) Atrophy of caudate nucleus is seen in Huntington disease.

(Choice E) Posterior column involvement is seen with both vitamin B 12 deficiency and syphilis.

(Choice F) The presence of Lewy bodies is characteristic of Parkinsonism.

Educational Objective:

nucleotide excision repair, and mismatch repair.

A number of inherited disorders are caused by deficient DNA-repair enzymes:

1. Ataxia-telangiectasia is characterized by DNA hypersensitivity to ionizing radiation.
2. In xeroderma pigmentosum, DNA is hypersensitive to UV radiation, causing premature skin aging and increased risk of skin cancer (malignant melanoma and squamous cell carcinoma).
3. Fanconi anemia is caused by hypersensitivity of DNA to cross-linking agents.
4. Bloom syndrome is characterized by generalized chromosomal instability. Increased susceptibility to neoplasms is present.
5. Hereditary nonpolyposis colorectal cancer (HNPCC) occurs due to a defect in DNA mismatch-repair enzymes. It leads to increased susceptibility to colon cancer.

(Choice A) Neurofibrillary tangles in the neocortex are seen in Alzheimer disease.

(Choice C) Loss of neurons in the substantia nigra is characteristic of Parkinson disease.

(Choice D) Atrophy of caudate nucleus is seen in Huntington disease.

(Choice E) Posterior column involvement is seen with both vitamin B 12 deficiency and syphilis.

(Choice F) The presence of Lewy bodies is characteristic of Parkinsonism.

Educational Objective:
Ataxia-telangiectasia is an autosomal-recessive disorder resulting from a defect in DNA-repair genes. The DNA of these patients is hypersensitive to ionizing radiation. Manifestations include cerebellar ataxia, oculocutaneous telangiectasias, repeated sinopulmonary infections, and an increased incidence of malignancy.

Pathology	Nervous System	Ataxia telangiectasia
Subject	System	Topic

Copyright © UWorld. All rights reserved.

A 44-year-old man with a history of advanced HIV is brought to the office by his family due to progressive cognitive decline. Over the last several years he has had worsening memory deficits and difficulty carrying out simple mental tasks. The patient has had no headaches, slurred speech, muscle weakness, or changes in vision. He was diagnosed with HIV 7 years ago, but his medical follow-up and treatment compliance have been poor. The patient does not use tobacco, alcohol, or illicit drugs. Vital signs are normal. He has difficulty with delayed recall as well as several executive function tasks. The remainder of his neurologic examination is unremarkable. Two weeks later, he dies from severe pneumonia and respiratory failure. Which of the following histopathologic findings would most likely be found on biopsy of this patient's brain?

A. Amyloid deposits in the cortical blood vessels

B. Congo red staining plaques in the hippocampus

C. Eosinophilic, round, cytoplasmic neuronal inclusions

D. Microglial nodules and multinucleated giant cells

E. Profound neuronal loss in the caudate nucleus

F. Slit-like white matter cavities with surrounding gliosis

Submit

A 44-year-old man with a history of advanced HIV is brought to the office by his family due to progressive cognitive decline. Over the last several years he has had worsening memory deficits and difficulty carrying out simple mental tasks. The patient has had no headaches, slurred speech, muscle weakness, or changes in vision. He was diagnosed with HIV 7 years ago, but his medical follow-up and treatment compliance have been poor. The patient does not use tobacco, alcohol, or illicit drugs. Vital signs are normal. He has difficulty with delayed recall as well as several executive function tasks. The remainder of his neurologic examination is unremarkable. Two weeks later, he dies from severe pneumonia and respiratory failure. Which of the following histopathologic findings would most likely be found on biopsy of this patient's brain?

- A. Amyloid deposits in the cortical blood vessels (5%)
- B. Congo red staining plaques in the hippocampus (16%)
- C. Eosinophilic, round, cytoplasmic neuronal inclusions (17%)
- ✓ D. Microglial nodules and multinucleated giant cells (42%)
- E. Profound neuronal loss in the caudate nucleus (3%)
- F. Slit-like white matter cavities with surrounding gliosis (15%)

Omitted
Correct answer
D

42%
Answered correctly

01 sec
Time Spent

06/11/2020
Last Updated

Explanation

This patient with a history of long-standing HIV infection, medical noncompliance, and progressive cognitive decline likely had **HIV-associated dementia**. Most cases occur in those with advanced HIV who have CD4 counts <200/mm^3. Patients usually develop features of **subcortical**

This patient with a history of long-standing HIV infection, medical noncompliance, and progressive cognitive decline likely had **HIV-associated dementia**. Most cases occur in those with advanced HIV who have CD4 counts <200/mm^3. Patients usually develop features of **subcortical** dementia, including attention or working memory deficits, executive dysfunction, and slow information processing.

HIV enters the central nervous system via infected monocytes and establishes a productive infection in **microglial cells** (resident macrophages of the central nervous system) and blood-derived perivascular macrophages. Activation of these cells occurs in response to the infection, inflammatory cytokines, and HIV-derived proteins, which leads them to cluster around small areas of necrosis (forming **microglial nodules**) and fuse together to form **multinucleated giant cells**. Because HIV does not directly infect neurons, the underlying pathology of HIV-associated dementia is thought to stem from the **release of neurotoxic compounds** by these activated monocytes.

(Choices A and B) Cerebral amyloid angiopathy is marked by beta-amyloid deposits in the walls of cortical blood vessels. This condition is usually asymptomatic but can be associated with intracerebral hemorrhage or Alzheimer dementia. Alzheimer dementia is also associated with neuritic (senile) plaques, which are extracellular deposits of beta-amyloid surrounded by dystrophic neurites; they stain positive with Congo red and are often located in the hippocampus. Alzheimer dementia is typically seen in older adults and is characterized by slowly progressive memory impairment and higher cortical dysfunction (eg, aphasia, agnosia, apraxia).

(Choice C) Patients with rabies develop eosinophilic inclusion bodies in the cytoplasm of neuronal cells (Negri bodies). Rabies is a neurotropic virus that is transmitted by the saliva of infected animals, usually via a bite wound. Patients classically develop fever, hydrophobia (fear of water), and pharyngeal spasms.

(Choice E) Huntington disease is an autosomal dominant disorder that causes choreiform movement, psychiatric disturbances, and dementia. It is characterized by severe neuronal loss in the caudate nucleus.

(Choice F) Lacunar infarctions cause slit-like white matter cavities with surrounding gliosis. Recurrent lacunar infarctions can result in vascular dementia, which is often characterized by sudden/stepwise cognitive decline and focal neurologic deficits. Patients with vascular dementia are typically older and usually have cardiovascular risk factors.

Educational objective:
HIV-associated dementia should be suspected in patients with AIDS who have progressive cognitive decline. The characteristic histopathologic finding is microglial nodules (groups of activated microglia/macrophages around small areas of necrosis) and multinucleated giant cells.

dementia. Most cases occur in those with advanced HIV who have CD4 counts <200/mm³. Patients usually develop features of **subcortical**

Exhibit Display

Zoom In | Zoom Out | Reset | Add To New Card | Existing Card

References

(Choices A and B) Cerebral amyloid angiopathy is marked by beta-amyloid deposits in the walls of cortical blood vessels. This condition is usually asymptomatic but can be associated with intracerebral hemorrhage or Alzheimer dementia. Alzheimer dementia is also associated with neuritic (senile) plaques, which are extracellular deposits of beta-amyloid surrounded by dystrophic neurites; they stain positive with Congo red and are often located in the hippocampus. Alzheimer dementia is typically seen in older adults and is characterized by slowly progressive memory impairment and higher cortical dysfunction (eg, aphasia, agnosia, apraxia).

(Choice C) Patients with rabies develop eosinophilic inclusion bodies in the cytoplasm of neuronal cells (Negri bodies). Rabies is a neurotropic virus that is transmitted by the saliva of infected animals, usually via a bite wound. Patients classically develop fever, hydrophobia (fear of water), and pharyngeal spasms.

(Choice E) Huntington disease is an autosomal dominant disorder that causes choreiform movement, psychiatric disturbances, and dementia. It is characterized by severe neuronal loss in the caudate nucleus.

(Choice F) Lacunar infarctions cause slit-like white matter cavities with surrounding gliosis. Recurrent lacunar infarctions can result in vascular dementia, which is often characterized by sudden/stepwise cognitive decline and focal neurologic deficits. Patients with vascular dementia are typically older and usually have cardiovascular risk factors.

Educational objective:
HIV-associated dementia should be suspected in patients with AIDS who have progressive cognitive decline. The characteristic histopathologic finding is microglial nodules (groups of activated microglia/macrophages around small areas of necrosis) and multinucleated giant cells.

References

- Etiology of microglial nodules in brains of patients with acquired immunodeficiency syndrome.
- Pathways to neuronal injury and apoptosis in HIV-associated dementia.

Pathology	Nervous System	HIV
Subject	System	Topic

Copyright © UWorld. All rights reserved.

A 54-year-old previously healthy man comes to the office due to progressive fatigue and weakness for the past 2 months. His weakness predominantly involves the lower extremities, causing him to have difficulty rising from a chair. The patient also has a persistent cough and unintentional 7-kg (15.4-lb) weight loss during the same period. He has a 30-pack-year smoking history and drinks alcohol occasionally. Physical examination shows bilaterally decreased strength in the proximal muscles of the lower extremities with normal bulk and tone. Quadriceps tendon reflexes are diminished bilaterally. Chest x-ray reveals a hilar mass, biopsy of which demonstrates small cells that stain positive for chromogranin and synaptophysin. Which of the following is the most likely cause of this patient's muscle weakness?

A. Antibodies against voltage-gated calcium channels

B. Antibodies against nicotinic acetylcholine receptors

C. Immune-mediated, segmental axonal demyelination

D. Neoplastic deposits in the spinal cord epidural space

E. Ubiquitin-proteasome-mediated muscle protein degradation

Submit

A 54-year-old previously healthy man comes to the office due to progressive fatigue and weakness for the past 2 months. His weakness predominantly involves the lower extremities, causing him to have difficulty rising from a chair. The patient also has a persistent cough and unintentional 7-kg (15.4-lb) weight loss during the same period. He has a 30-pack-year smoking history and drinks alcohol occasionally. Physical examination shows bilaterally decreased strength in the proximal muscles of the lower extremities with normal bulk and tone. Quadriceps tendon reflexes are diminished bilaterally. Chest x-ray reveals a hilar mass, biopsy of which demonstrates small cells that stain positive for chromogranin and synaptophysin. Which of the following is the most likely cause of this patient's muscle weakness?

- ✓ A. Antibodies against voltage-gated calcium channels (77%)
- B. Antibodies against nicotinic acetylcholine receptors (8%)
- C. Immune-mediated, segmental axonal demyelination (4%)
- D. Neoplastic deposits in the spinal cord epidural space (8%)
- E. Ubiquitin-proteasome-mediated muscle protein degradation (2%)

Omitted
Correct answer
A

77%
Answered correctly

02 secs
Time Spent

04/07/2020
Last Updated

Explanation

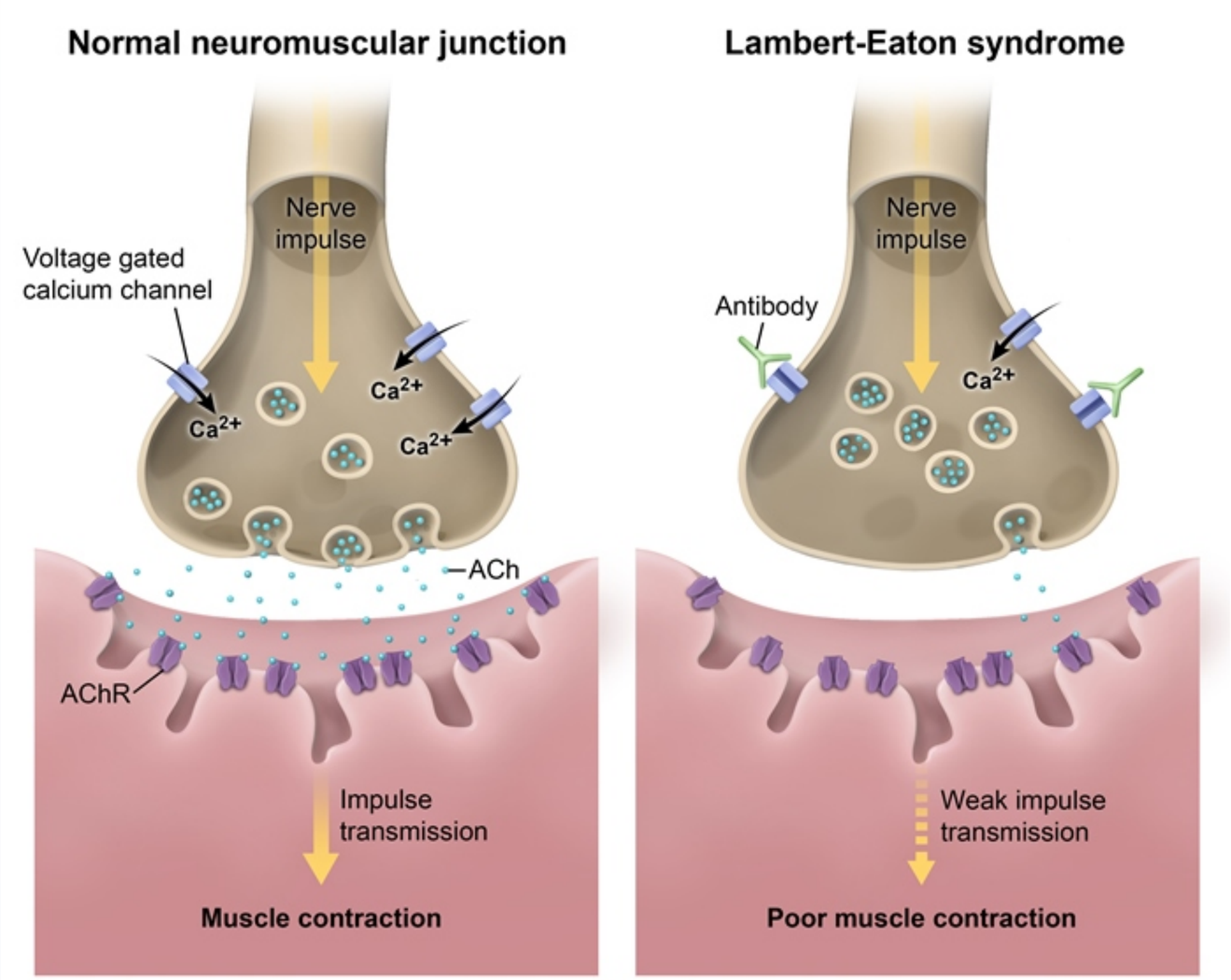

ACh = acetylcholine; **AChR** = acetylcholine receptor.

©UWorld

©UWorld

This patient with small cell lung cancer (small cells with neuroendocrine differentiation) has progressive proximal muscle weakness and diminished reflexes in the lower extremities, suggestive of paraneoplastic **Lambert-Eaton myasthenic syndrome** (LEMS). LEMS is an autoimmune disorder characterized by **antibodies against presynaptic voltage-gated calcium channels** at the neuromuscular junction. Normally, these calcium channels open in response to a presynaptic action potential, leading to an influx of calcium ions that cause synaptic vesicle fusion and acetylcholine release. LEMS-associated autoantibodies inhibit calcium influx, resulting in reduced acetylcholine release and failure to provoke muscular contractions.

Muscular weakness in LEMS is progressive and predominantly involves the **proximal muscles**; it typically affects the **lower limbs** (eg, difficulty rising from a chair or climbing stairs) before the upper limbs (eg, raising arms above the head). **Deep tendon reflexes** are typically **diminished** or absent. Both strength and reflexes improve transiently with isometric muscular contractions in a phenomenon known as **postexercise facilitation**, likely due to a buildup of intracellular calcium with repetitive stimuli. Approximately 50% of patients have an underlying malignancy, most commonly **small cell lung cancer**.

(Choice B) Autoantibodies against postsynaptic nicotinic acetylcholine receptors cause myasthenia gravis (MG), another immune-mediated neuromuscular disorder. MG typically involves the extraocular (eg, ptosis, diplopia) and bulbar (eg, dysphonia, dysphagia) muscles before affecting the limbs, and reflexes typically remain intact.

(Choice C) Guillain-Barré syndrome occurs due to immune-mediated, segmental axonal demyelination; however, it typically occurs after an upper respiratory or gastrointestinal (eg, *Campylobacter*) infection. Rapidly progressive ascending paralysis (distal prior to proximal muscle involvement) is characteristic.

(Choice D) Metastatic disease within the epidural space can cause spinal cord compression. Patients typically develop spastic paraparesis below the level of involvement. Hyperreflexia is common, and urine and stool retention may be seen (depending on the level of involvement).

(Choice E) Protein degradation in cancer cachexia is associated with activation of the ubiquitin-proteasome system. Cancer cachexia causes muscle and fat loss, but weakness would be expected to affect proximal and distal muscles equally and reflexes are preserved.

Educational objective:
Lambert-Eaton myasthenic syndrome is characterized by antibodies against presynaptic voltage-gated calcium channels. Patients develop

Muscular weakness in LEMS is progressive and predominantly involves the **proximal muscles**; it typically affects the **lower limbs** (eg, difficulty rising from a chair or climbing stairs) before the upper limbs (eg, raising arms above the head). **Deep tendon reflexes** are typically **diminished** or absent. Both strength and reflexes improve transiently with isometric muscular contractions in a phenomenon known as **postexercise facilitation**, likely due to a buildup of intracellular calcium with repetitive stimuli. Approximately 50% of patients have an underlying malignancy, most commonly **small cell lung cancer**.

(Choice B) Autoantibodies against postsynaptic nicotinic acetylcholine receptors cause myasthenia gravis (MG), another immune-mediated neuromuscular disorder. MG typically involves the extraocular (eg, ptosis, diplopia) and bulbar (eg, dysphonia, dysphagia) muscles before affecting the limbs, and reflexes typically remain intact.

(Choice C) Guillain-Barré syndrome occurs due to immune-mediated, segmental axonal demyelination; however, it typically occurs after an upper respiratory or gastrointestinal (eg, *Campylobacter*) infection. Rapidly progressive ascending paralysis (distal prior to proximal muscle involvement) is characteristic.

(Choice D) Metastatic disease within the epidural space can cause spinal cord compression. Patients typically develop spastic paraparesis below the level of involvement. Hyperreflexia is common, and urine and stool retention may be seen (depending on the level of involvement).

(Choice E) Protein degradation in cancer cachexia is associated with activation of the ubiquitin-proteasome system. Cancer cachexia causes muscle and fat loss, but weakness would be expected to affect proximal and distal muscles equally and reflexes are preserved.

Educational objective:
Lambert-Eaton myasthenic syndrome is characterized by antibodies against presynaptic voltage-gated calcium channels. Patients develop progressive proximal muscle weakness with reduced/absent reflexes that predominantly involves the lower extremities. The syndrome is often associated with malignancy, particularly small cell lung cancer.

Pathology	Nervous System	Eaton lambert myasthenic syndrome
Subject	System	Topic

Copyright © UWorld. All rights reserved.

Muscular weakness in LEMS is progressive and predominantly involves the **proximal muscles**; it typically affects the **lower limbs** (eg, difficulty rising from a chair or clim ... ed or absent. Both strength ar ... **facilitation**, likely due to ... cy, most commonly **small c**

(Choice B) Autoantibod ... neuromuscular disorder. ... affecting the limbs, and r

(Choice C) Guillain-Bar ... upper respiratory or gastrointes ... ment) is characteristic.

(Choice D) Metastatic d ... below the level of involve

(Choice E) Protein degr ... s muscle and fat loss, but

Educational objective: Lambert-Eaton myasther ... progressive proximal mu ... n associated with malignar

Pathology — Subject
Nervou — System

Copyright © UWorld. All rights reserved.

Exhibit Display

Autoimmune-mediated neuromuscular junction disorders		
	Myasthenia gravis	**Lambert-Eaton myasthenic syndrome**
Antibodies	Acetylcholine receptor antibody	Voltage-gated calcium channel antibody
Location of defect	Postsynaptic	Presynaptic
Weakness	Extraocular & bulbar affected first (eg, ptosis, diplopia)	Proximal muscles affected first (eg, weakness standing from chair)
Deep-tendon reflexes	Intact	Decreased/absent
Autonomic dysfunction	Rare	Common
Association	Thymoma/thymic hyperplasia	Malignancy (eg, small cell lung cancer)
Tensilon test (edrophonium)	Improves weakness	No change
Response to exercise	Decreased strength	Increased strength
Nerve stimulation	Decremental response	Incremental response

Add To New Card | Existing Card

Muscular weakness in LEMS is progressive and predominantly involves the **proximal muscles**; it typically affects the **lower limbs** (eg, difficulty rising from a chair or clim
absent. Both strength ar
facilitation, likely due to
most commonly **small ce**

(Choice B) Autoantibod
neuromuscular disorder.
affecting the limbs, and r

(Choice C) Guillain-Bar
respiratory or gastrointes
is characteristic.

(Choice D) Metastatic d
below the level of involve

(Choice E) Protein degr
muscle and fat loss, but

Educational objective:
Lambert-Eaton myasther
progressive proximal mu
associated with malignar

Pathology — Subject
Nervou — System

Exhibit Display

Autoimmune-mediated neuromuscular junction disorders		
	Myasthenia gravis	**Lambert-Eaton myasthenic syndrome**
Antibodies	Acetylcholine receptor antibody	Voltage-gated calcium channel antibody
Location of defect	Postsynaptic	Presynaptic
Weakness	Extraocular & bulbar affected first (eg, ptosis, diplopia)	Proximal muscles affected first (eg, weakness standing from chair)
Deep-tendon reflexes	Intact	Decreased/absent
Autonomic dysfunction	Rare	Common
Association	Thymoma/thymic hyperplasia	Malignancy (eg, small cell lung cancer)
Tensilon test (edrophonium)	Improves weakness	No change
Response to exercise	Decreased strength	Increased strength
Nerve stimulation studies	Decremental response	Incremental response

Add To New Card | Existing Card

Copyright © UWorld. All rights reserved.

A 16-year-old boy is being evaluated for difficulty walking. On physical examination, he has thoracic scoliosis and multiple small scars on his hands. When asked about these, the boy replies, "I frequently burn my hands by accident because I can't feel the heat." Neurologic examination reveals 1+ biceps reflexes and 3+ patellar reflexes bilaterally, as well as decreased muscle strength in the bilateral upper and lower extremities. His hand muscles are atrophic, and position and vibration senses in the feet are also impaired. Which of the following is the most likely cause of this patient's problems?

A. Amyotrophic lateral sclerosis
B. Guillain-Barré syndrome
C. Medulloblastoma
D. Multiple sclerosis
E. Normal pressure hydrocephalus
F. Syringomyelia

Submit

A 16-year-old boy is being evaluated for difficulty walking. On physical examination, he has thoracic scoliosis and multiple small scars on his hands. When asked about these, the boy replies, "I frequently burn my hands by accident because I can't feel the heat." Neurologic examination reveals 1+ biceps reflexes and 3+ patellar reflexes bilaterally, as well as decreased muscle strength in the bilateral upper and lower extremities. His hand muscles are atrophic, and position and vibration senses in the feet are also impaired. Which of the following is the most likely cause of this patient's problems?

- A. Amyotrophic lateral sclerosis (23%)
- B. Guillain-Barré syndrome (5%)
- C. Medulloblastoma (5%)
- D. Multiple sclerosis (4%)
- E. Normal pressure hydrocephalus (0%)
- ✓ F. Syringomyelia (60%)

Omitted
Correct answer
F

60%
Answered correctly

02 secs
Time Spent

05/04/2020
Last Updated

Explanation

Syringomyelia

Discriminative touch, proprioception

Pain, temperature

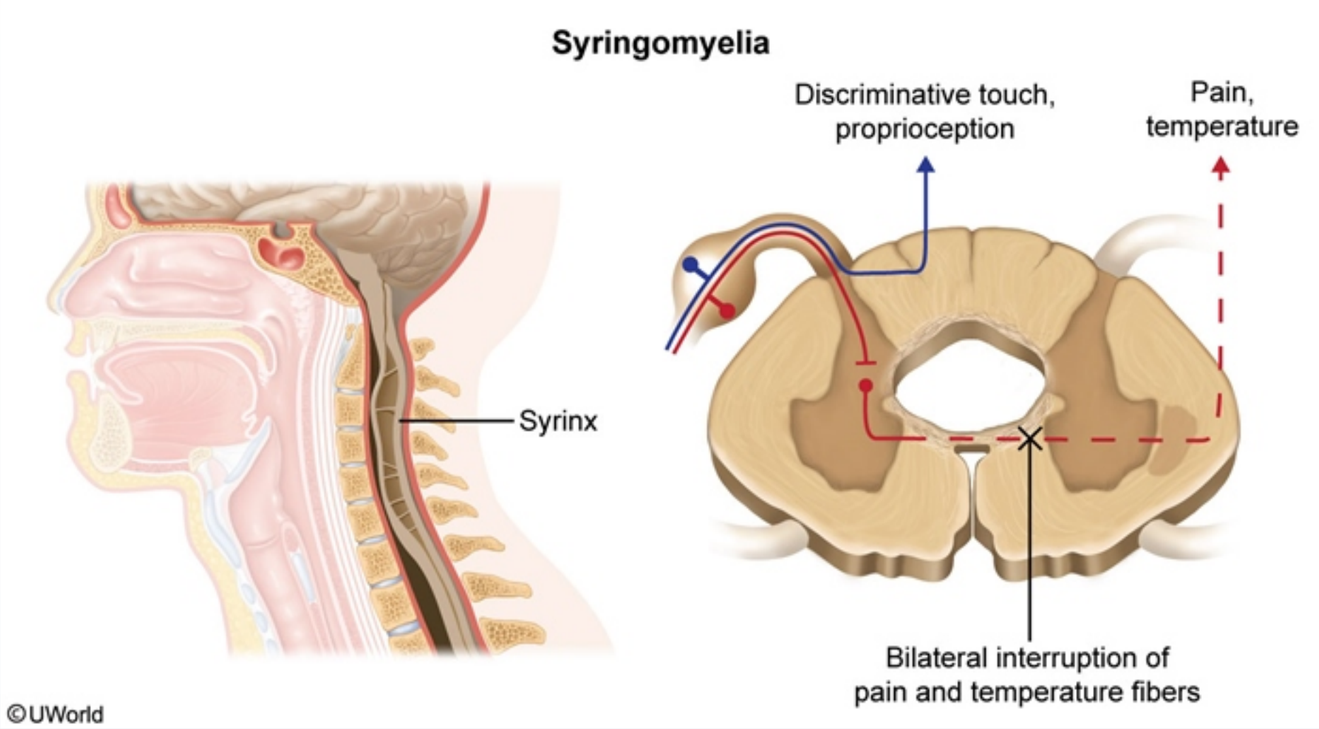

This patient has chronic **loss of upper extremity pain and temperature sensations**, upper extremity weakness and hyporeflexia, lower extremity weakness and hyperreflexia, and kyphoscoliosis. These findings are consistent with **syringomyelia**.

In syringomyelia, a **central cystic dilation** in the cervical spinal cord (a syrinx) slowly enlarges, characteristically causing damage to the **ventral white commissure** and **anterior horns**. The ventral white commissure is the site of decussation of second-order lateral spinothalamic tract neurons, and the ventral horns are the site of lower motor neuron cell bodies. The syrinx is most commonly situated at the C8-T1 cord levels and may extend rostrally, caudally, and centrifugally. Further expansion within the cervical cord in later stages of the disease can produce lower extremity weakness and hyperreflexia (an upper motor neuron defect) by affecting the lateral corticospinal tract and can also lead to loss of position and vibration senses in the feet due to involvement of the posterior columns. Scoliosis can occur due to paresis of paravertebral muscles.

©UWorld

pain and temperature fibers

This patient has chronic **loss of upper extremity pain and temperature sensations**, upper extremity weakness and hyporeflexia, lower extremity weakness and hyperreflexia, and kyphoscoliosis. These findings are consistent with **syringomyelia**.

In syringomyelia, a **central cystic dilation** in the cervical spinal cord (a syrinx) slowly enlarges, characteristically causing damage to the **ventral white commissure** and **anterior horns**. The ventral white commissure is the site of decussation of second-order lateral spinothalamic tract neurons, and the ventral horns are the site of lower motor neuron cell bodies. The syrinx is most commonly situated at the C8-T1 cord levels and may extend rostrally, caudally, and centrifugally. Further expansion within the cervical cord in later stages of the disease can produce lower extremity weakness and hyperreflexia (an upper motor neuron defect) by affecting the lateral corticospinal tract and can also lead to loss of position and vibration senses in the feet due to involvement of the posterior columns. Scoliosis can occur due to paresis of paravertebral muscles.

(Choice A) Amyotrophic lateral sclerosis is a progressive degenerative disease of upper and lower motor neurons only; it does not cause sensory loss.

(Choice B) Guillain-Barré syndrome is a peripheral nervous system autoimmune demyelinating polyneuropathy that typically causes lower motor neuron manifestations (eg, areflexia, weakness) in a symmetric ascending pattern.

(Choice C) Medulloblastoma is the most common malignant central nervous system (CNS) tumor in children, with pilocytic astrocytoma, a low-grade astrocytoma, being the most common CNS tumor overall. Medulloblastoma is a posterior fossa tumor that causes symptoms related to obstructive hydrocephalus.

(Choice D) Multiple sclerosis is an autoimmune CNS demyelinating disorder that presents with episodic neurologic symptoms reflecting defects in various white matter tracts.

(Choice E) Normal pressure hydrocephalus is characterized by gait ataxia and urinary incontinence. It is rare in patients age <60. Defective cerebrospinal fluid resorption by the arachnoid granulations gives rise to the secondary form of this disease.

Educational objective:
The combination of fixed segmental loss of upper extremity pain and temperature sensations, upper extremity lower motor neuron signs, and/or lower extremity upper motor neuron signs in the setting of scoliosis suggests syringomyelia.

white commissure and **anterior horns**. The ventral white commissure is the site of decussation of second-order lateral spinothalamic tract neurons, and the ventral horns are the site of lower motor neuron cell bodies. The syrinx is most commonly situated at the C8-T1 cord levels and may extend rostrally, caudally, and centrifugally. Further expansion within the cervical cord in later stages of the disease can produce lower extremity weakness and hyperreflexia (an upper motor neuron defect) by affecting the lateral corticospinal tract and can also lead to loss of position and vibration senses in the feet due to involvement of the posterior columns. Scoliosis can occur due to paresis of paravertebral muscles.

(Choice A) Amyotrophic lateral sclerosis is a progressive degenerative disease of upper and lower motor neurons only; it does not cause sensory loss.

(Choice B) Guillain-Barré syndrome is a peripheral nervous system autoimmune demyelinating polyneuropathy that typically causes lower motor neuron manifestations (eg, areflexia, weakness) in a symmetric ascending pattern.

(Choice C) Medulloblastoma is the most common malignant central nervous system (CNS) tumor in children, with pilocytic astrocytoma, a low-grade astrocytoma, being the most common CNS tumor overall. Medulloblastoma is a posterior fossa tumor that causes symptoms related to obstructive hydrocephalus.

(Choice D) Multiple sclerosis is an autoimmune CNS demyelinating disorder that presents with episodic neurologic symptoms reflecting defects in various white matter tracts.

(Choice E) Normal pressure hydrocephalus is characterized by gait ataxia and urinary incontinence. It is rare in patients age <60. Defective cerebrospinal fluid resorption by the arachnoid granulations gives rise to the secondary form of this disease.

Educational objective:
The combination of fixed segmental loss of upper extremity pain and temperature sensations, upper extremity lower motor neuron signs, and/or lower extremity upper motor neuron signs in the setting of scoliosis suggests syringomyelia.

Pathology	Nervous System	Syringomyelia
Subject	System	Topic

Copyright © UWorld. All rights reserved.

A 65-year-old man is brought to the emergency department due to acute onset of a severe headache and dizziness. He describes it as a throbbing that localizes to the back of his head, with associated vertigo and mild nausea. The patient has a past medical history of type 2 diabetes mellitus, hypertension, chronic obstructive pulmonary disease, and a recent diagnosis of lung adenocarcinoma. He has smoked 1-2 packs of cigarettes daily for the past 30 years. His temperature is 36.7 C (98 F), blood pressure is 170/96 mm Hg, pulse is 80/min, and respirations are 14/min. Noncontrast head CT reveals an acute hemorrhage in the cerebellar vermis without mass effect or midline shift. Which of the following neurologic findings is most likely to be present during this patient's physical examination?

A. Complete ptosis
B. Dysphagia
C. Hemiparesis
D. Limb dysmetria
E. Resting tremor
F. Truncal ataxia

Submit

A 65-year-old man is brought to the emergency department due to acute onset of a severe headache and dizziness. He describes it as a throbbing that localizes to the back of his head, with associated vertigo and mild nausea. The patient has a past medical history of type 2 diabetes mellitus, hypertension, chronic obstructive pulmonary disease, and a recent diagnosis of lung adenocarcinoma. He has smoked 1-2 packs of cigarettes daily for the past 30 years. His temperature is 36.7 C (98 F), blood pressure is 170/96 mm Hg, pulse is 80/min, and respirations are 14/min. Noncontrast head CT reveals an acute hemorrhage in the cerebellar vermis without mass effect or midline shift. Which of the following neurologic findings is most likely to be present during this patient's physical examination?

- A. Complete ptosis (1%)
- B. Dysphagia (0%)
- C. Hemiparesis (1%)
- D. Limb dysmetria (8%)
- E. Resting tremor (1%)
- ✓ F. Truncal ataxia (85%)

Omitted
Correct answer
F

85%
Answered correctly

01 sec
Time Spent

05/17/2020
Last Updated

Explanation

Functional anatomy of the cerebellum

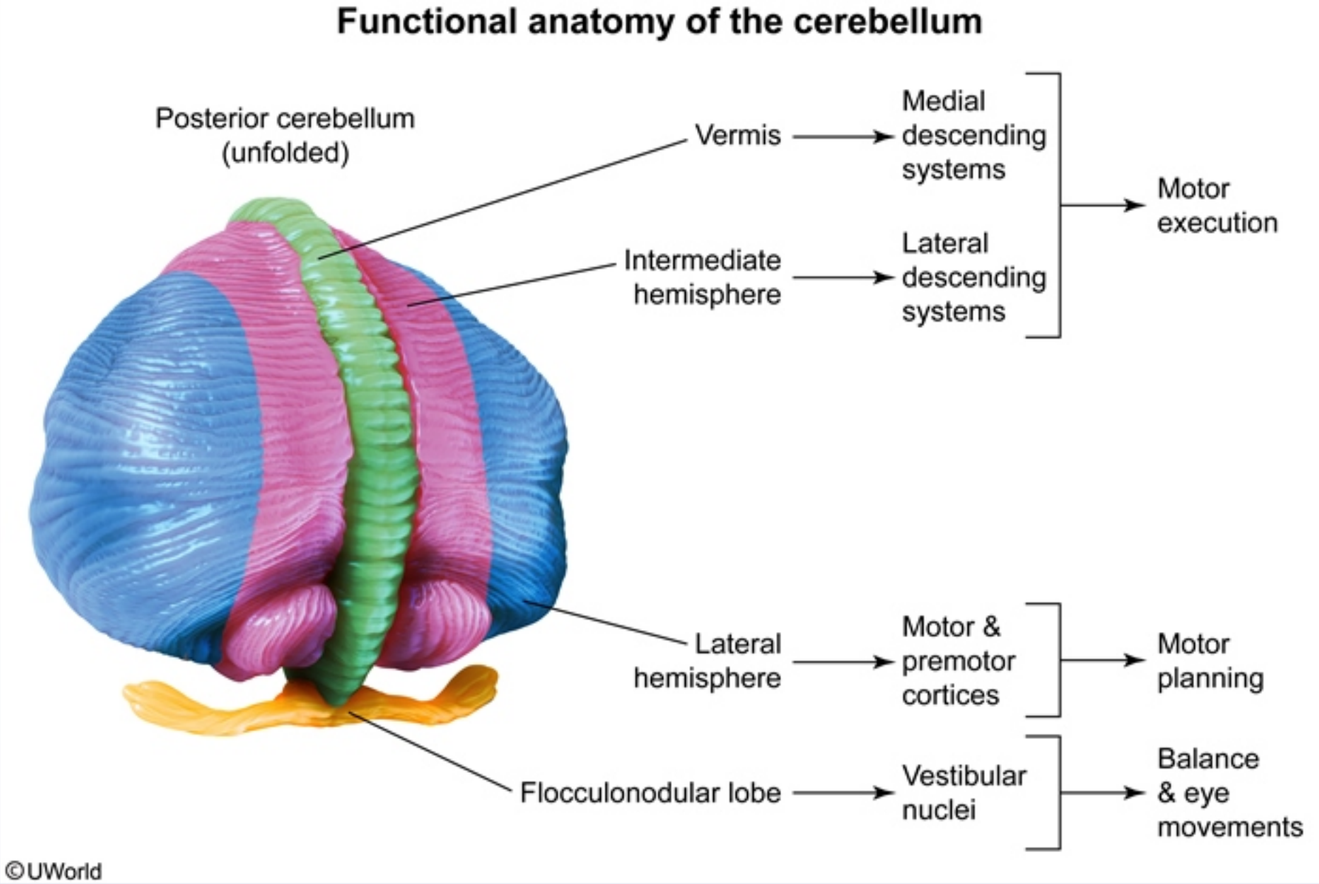

The **cerebellar vermis** modulates axial/truncal posture and coordination via connections with the **medial** descending motor systems (eg, anterior corticospinal, reticulospinal, vestibulospinal, and tectospinal tracts). Consequently, acute lesions to this region (eg, due to hemorrhage) typically result in **truncal ataxia**, characterized by a wide-based, unsteady gait. Patients may also develop **vertigo and nystagmus** due to involvement of the inferior vermis and the flocculonodular lobe (vestibulocerebellum), which modulate balance and ocular movements via connections with the vestibular nuclei and medial longitudinal fasciculus.

©UWorld

The **cerebellar vermis** modulates axial/truncal posture and coordination via connections with the **medial** descending motor systems (eg, anterior corticospinal, reticulospinal, vestibulospinal, and tectospinal tracts). Consequently, acute lesions to this region (eg, due to hemorrhage) typically result in **truncal ataxia**, characterized by a wide-based, unsteady gait. Patients may also develop **vertigo and nystagmus** due to involvement of the inferior vermis and the flocculonodular lobe (vestibulocerebellum), which modulate balance and ocular movements via connections with the vestibular nuclei and medial longitudinal fasciculus.

Other features of cerebellar hemorrhage include nausea and occipital headache. Most cases are caused by hypertensive vasculopathy, but this patient's recent diagnosis of lung adenocarcinoma should also raise concern for hemorrhagic metastasis.

(Choice A) Complete ptosis from central lesions may result from injury to the oculomotor nerve fibers within the upper midbrain and is typically associated with contralateral hemiparesis due to adjacent corticospinal tract involvement (eg, Weber syndrome).

(Choice B) Oropharyngeal dysphagia is usually associated with lesions in the brainstem due to involvement of cranial nerves IX, X, and XII, and/or their nuclei. Cerebral cortical and subcortical lesions affecting the descending corticobulbar tracts may also lead to oropharyngeal dysphagia.

(Choice C) Hemiparesis results from lesions affecting the corticospinal tracts in the cerebral subcortical white matter and brainstem. Cerebellar lesions do not cause pyramidal tract signs or hemiparesis.

(Choice D) Limb dysmetria (overshoot/undershoot during targeted movement) is usually associated with lesions affecting the cerebellar hemispheres due to involvement of the **lateral** descending motor systems (eg, lateral corticospinal tract, rubrospinal tract). Hemispheric cerebellar lesions may also cause tremor during goal-directed activity (intention tremor).

(Choice E) Resting tremor is typically associated with parkinsonism due to damage of the substantia nigra and its projections to the striatum. Rubral tremor occurs at rest and during goal-directed activity and is associated with combined lesions to the midbrain, substantia nigra, and superior cerebellar peduncle due to disruption of cerebellothalamic pathways.

Educational objective:
Acute lesions to the cerebellar vermis typically cause truncal and gait ataxia due to impaired modulation of the medial-descending motor systems. Involvement of the lower vermis and the flocculonodular lobe also causes vertigo/nystagmus due to dysregulation of the vestibular nuclear

patient's recent diagnosis of lung adenocarcinoma should also raise concern for hemorrhagic metastasis.

(Choice A) Complete ptosis from central lesions may result from injury to the oculomotor nerve fibers within the upper midbrain and is typically associated with contralateral hemiparesis due to adjacent corticospinal tract involvement (eg, Weber syndrome).

(Choice B) Oropharyngeal dysphagia is usually associated with lesions in the brainstem due to involvement of cranial nerves IX, X, and XII, and/or their nuclei. Cerebral cortical and subcortical lesions affecting the descending corticobulbar tracts may also lead to oropharyngeal dysphagia.

(Choice C) Hemiparesis results from lesions affecting the corticospinal tracts in the cerebral subcortical white matter and brainstem. Cerebellar lesions do not cause pyramidal tract signs or hemiparesis.

(Choice D) Limb dysmetria (overshoot/undershoot during targeted movement) is usually associated with lesions affecting the cerebellar hemispheres due to involvement of the **lateral** descending motor systems (eg, lateral corticospinal tract, rubrospinal tract). Hemispheric cerebellar lesions may also cause tremor during goal-directed activity (intention tremor).

(Choice E) Resting tremor is typically associated with parkinsonism due to damage of the substantia nigra and its projections to the striatum. Rubral tremor occurs at rest and during goal-directed activity and is associated with combined lesions to the midbrain, substantia nigra, and superior cerebellar peduncle due to disruption of cerebellothalamic pathways.

Educational objective:
Acute lesions to the cerebellar vermis typically cause truncal and gait ataxia due to impaired modulation of the medial-descending motor systems. Involvement of the lower vermis and the flocculonodular lobe also causes vertigo/nystagmus due to dysregulation of the vestibular nuclear complex.

References

- Alternating skew deviation due to hemorrhage in the cerebellar vermis.
- Acute spontaneous cerebellar hemorrhage.
- Positional vertigo and the cerebellar vermis.

patient's recent diagnosis of lung adenocarcinoma should also raise concern for hemorrhagic metastasis.

(Choice A) Complete pt lly associated with contralat

(Choice B) Oropharyng and/or their nuclei. Cere dysphagia.

(Choice C) Hemiparesis llar lesions do not cause pyr

(Choice D) Limb dysme hemispheres due to invo bellar lesions may also cause t

(Choice E) Resting trem Rubral tremor occurs at superior cerebellar pedu

Educational objective:
Acute lesions to the cere ems. Involvement of the lower complex.

References

- Alternating skew dev
- Acute spontaneous c
- Positional vertigo and the cerebellar vermis.

Exhibit Display

0:00

A 65-year-old woman was brought to the clinic by her husband due to worsening memory problems. She had a medical history significant for long-standing hypertension, diabetes, and depression. Physical examination showed cognitive impairment but no focal neurologic deficits. Two years later, the patient dies suddenly from a massive myocardial infarction. Congo red staining of brain samples obtained from the hippocampus and cerebral arterioles reveals patchy red deposits that turn yellow-green under polarized light. This patient most likely suffered from which of the following conditions?

A. Alzheimer disease
B. Huntington disease
C. Parkinson disease
D. Pick disease
E. Pseudodementia
F. Vascular dementia
G. Vitamin B_{12} deficiency

Submit

A 65-year-old woman was brought to the clinic by her husband due to worsening memory problems. She had a medical history significant for long-standing hypertension, diabetes, and depression. Physical examination showed cognitive impairment but no focal neurologic deficits. Two years later, the patient dies suddenly from a massive myocardial infarction. Congo red staining of brain samples obtained from the hippocampus and cerebral arterioles reveals patchy red deposits that turn yellow-green under polarized light. This patient most likely suffered from which of the following conditions?

- ✓ A. Alzheimer disease (73%)
- B. Huntington disease (0%)
- C. Parkinson disease (0%)
- D. Pick disease (5%)
- E. Pseudodementia (2%)
- F. Vascular dementia (17%)
- G. Vitamin B_{12} deficiency (0%)

Omitted
Correct answer
A

73%
Answered correctly

02 secs
Time Spent

03/15/2020
Last Updated

Explanation

Amyloid is an abnormally folded (insoluble) fibrillar protein that deposits in the extracellular space of tissues. When stained with Congo red and viewed under polarized light, these deposits have a characteristic apple-green birefringence due to their ß-sheet structure. Amyloid deposition can

Amyloid is an abnormally folded (insoluble) fibrillar protein that deposits in the extracellular space of tissues. When stained with Congo red and viewed under polarized light, these deposits have a characteristic apple-green birefringence due to their β-sheet structure. Amyloid deposition can affect multiple organ systems, such as those involved in plasma cell tumors (eg, amyloid light chain protein [AL]) and chronic inflammatory diseases (eg, amyloid-associated protein [AA]).

However, in **Alzheimer disease**, amyloid deposits are seen exclusively in brain tissue. These deposits contain **beta-amyloid** (Aβ), which is formed by cleavage of amyloid precursor protein (a transmembrane glycoprotein). Early in the disease, neuritic (senile) plaques can be found in the medial temporal lobe (eg, hippocampus, amygdala, entorhinal cortex) and are composed of a central Aβ core surrounded by dystrophic neurites. Aβ deposition also occurs in the media/adventitia of cerebral vessels (amyloid angiopathy) and may cause vessel weakening with intracranial hemorrhage.

(Choice B) Huntington disease typically presents with dementia, choreiform movements, dystonia, and psychiatric symptoms. Patients characteristically have atrophy of the caudate and microscopy reveals intranuclear inclusions containing aggregates of huntingtin protein.

(Choice C) Parkinson disease usually presents with bradykinesia, rigidity, and tremor. Brain biopsy characteristically shows intracellular eosinophilic inclusions composed of α-synuclein (Lewy bodies).

(Choice D) Pick disease (frontotemporal dementia) typically presents with changes in personality/behavior and abnormal speech (eg, aphasia). Individuals usually have pronounced frontotemporal brain atrophy, and silver staining shows round cytoplasmic inclusions containing aggregates of tau protein (Pick bodies).

(Choice E) Elderly individuals may develop cognitive impairment in association with depression ("pseudodementia"); however, neuritic plaques and amyloid angiopathy would not be seen.

(Choice F) Vascular dementia typically presents with sudden/stepwise cognitive decline in patients with cardiovascular risk factors and ischemic stroke. The absence of glial scar formation on autopsy makes vascular dementia less likely in this patient.

(Choice G) Vitamin B_{12} deficiency is common in the elderly and may cause dementia, peripheral neuropathy, and/or subacute combined degeneration; however, neuritic plaques and amyloid angiopathy would not be seen.

Educational objective:

Exhibit Display

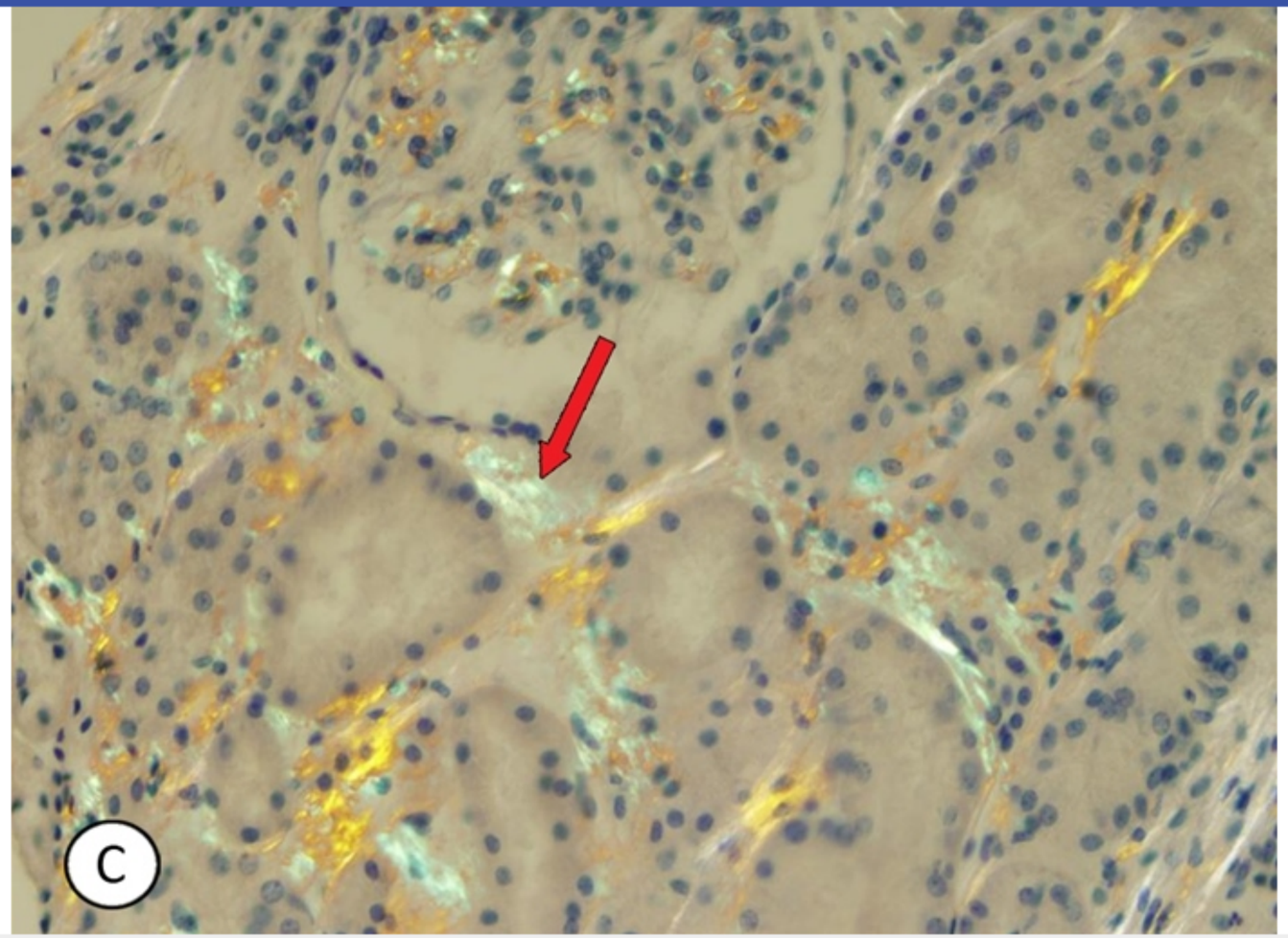

Zoom In
Zoom Out
Reset
Add To New Card | Existing Card

Educational objective:

Exhibit Display

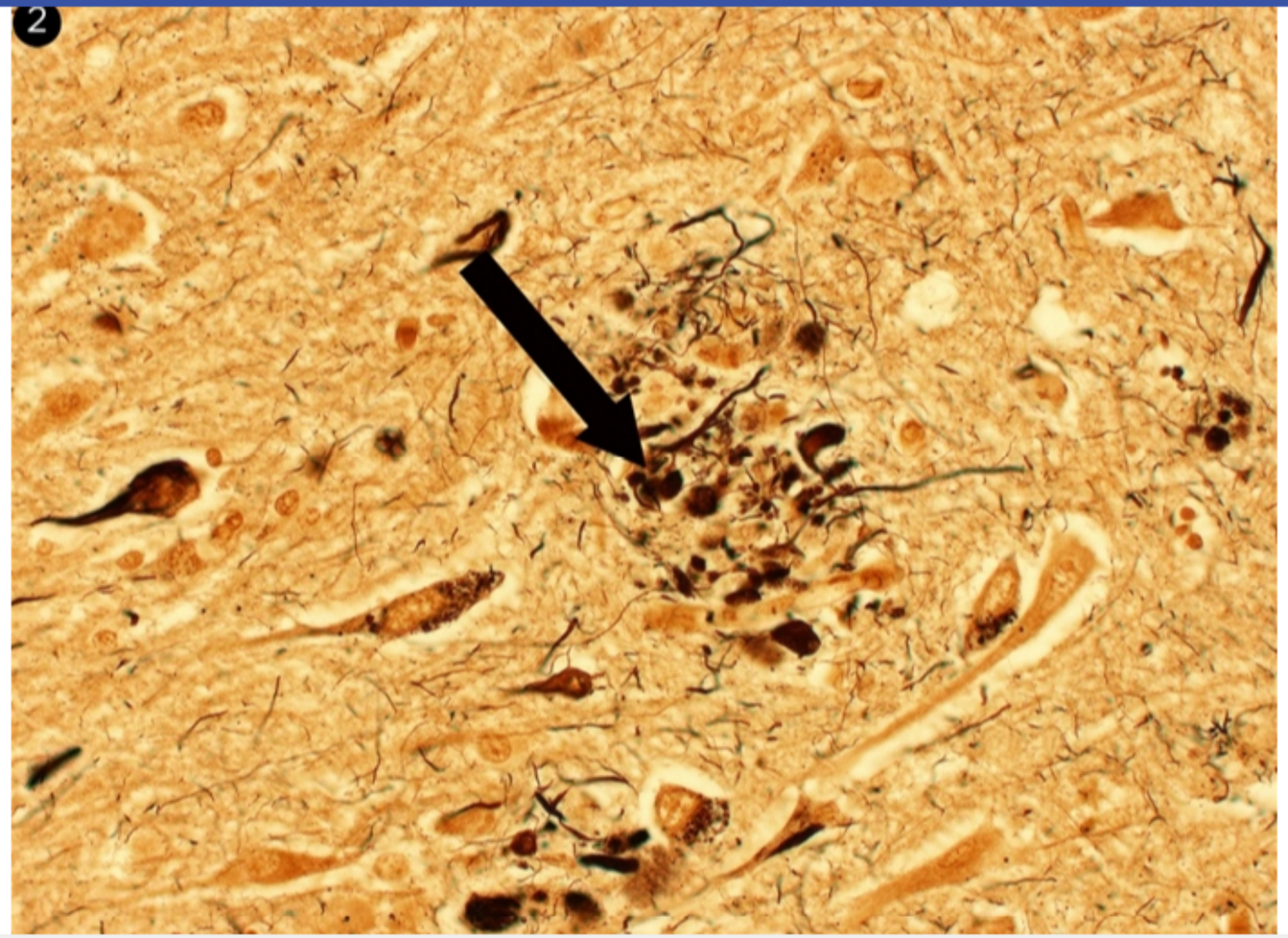

Zoom In | Zoom Out | Reset | Add To New Card | Existing Card

Educational objective:

1
2
3
4
5
6
7
8
9
10
11
12
13
14
15
16
17
18
19

Exhibit Display

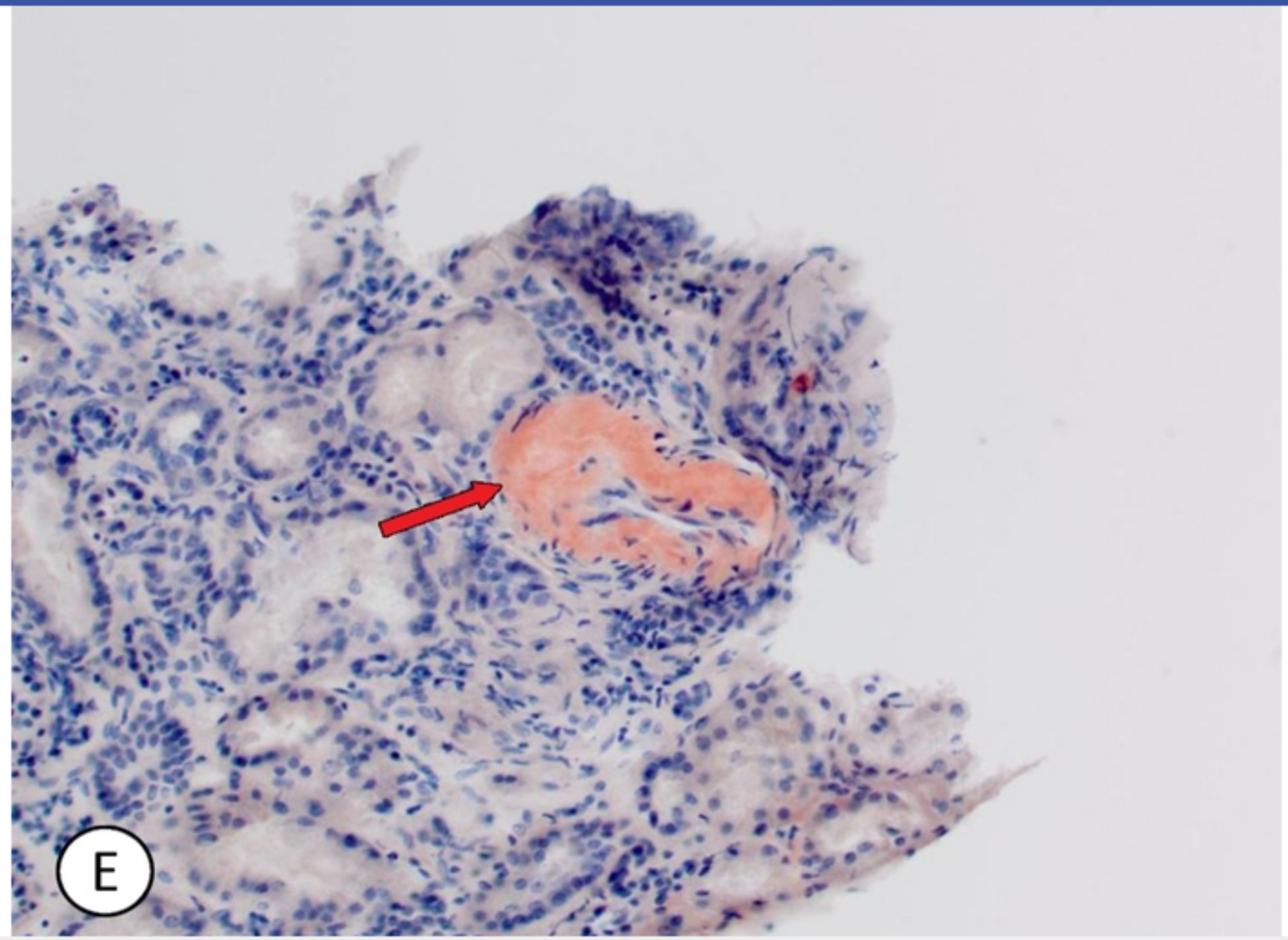

Zoom In | Zoom Out | Reset | Add To New Card | Existing Card

Educational objective:

1
2
3
4
5
6
7
8
9
10
11
12
13
14
15
16
17
18
19

Exhibit Display

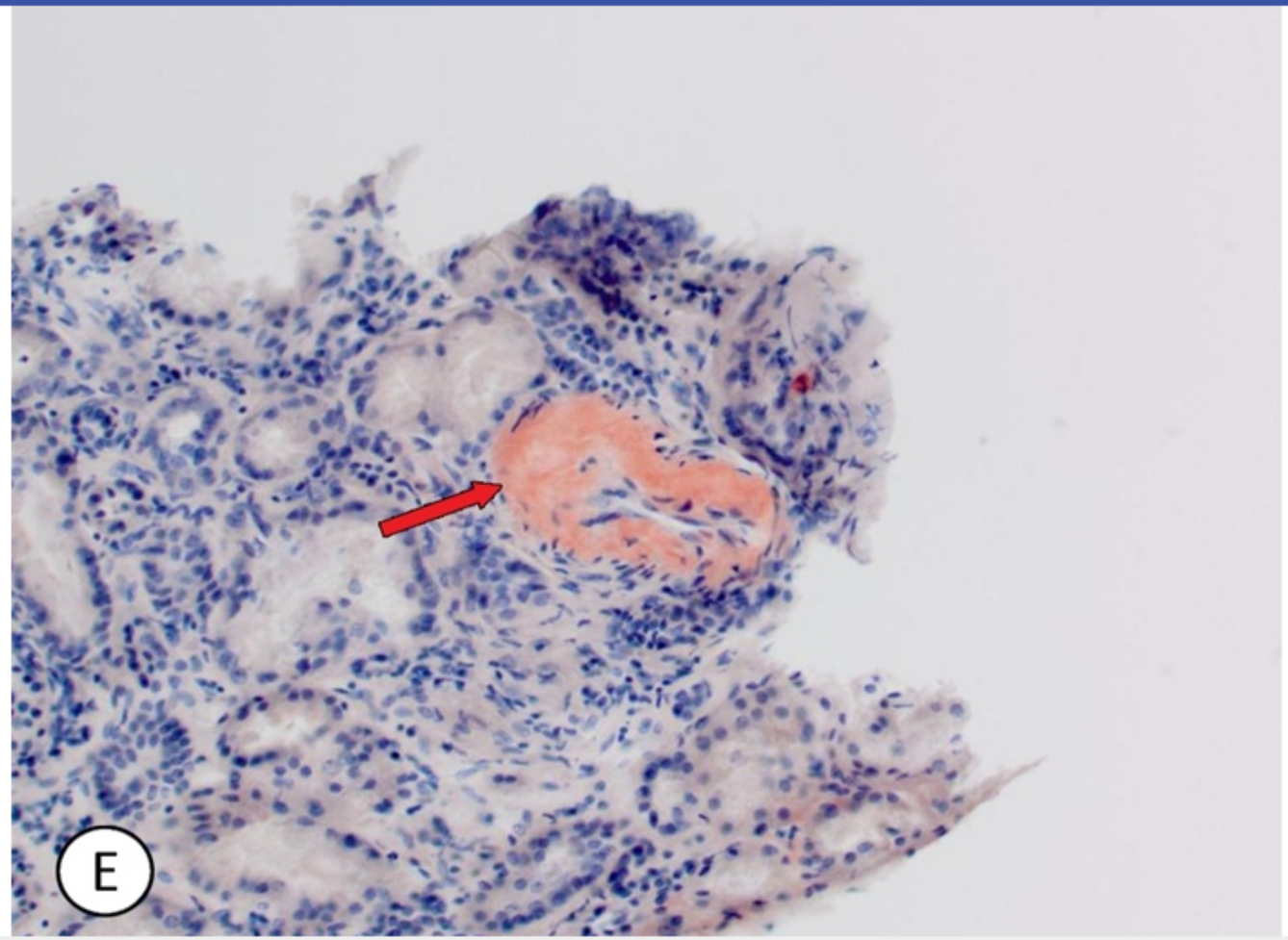

Zoom In | Zoom Out | Reset | Add To New Card | Existing Card

Educational objective:

A 35-year-old woman comes to the office due to trouble seeing out of her right eye. The patient started having blurry vision and pain with eye movement 2 days ago. She has no headache, vertigo, slurred speech, numbness, or weakness. Two years ago, the patient had an episode of double vision that spontaneously resolved after a few weeks. On physical examination, she has an afferent pupillary defect with markedly reduced visual acuity on the right. Funduscopy reveals blurring of the optic disk margins in the right eye. MRI of the brain reveals multiple, ovoid white matter lesions with perpendicular orientation to the lateral ventricles. This patient's condition is most likely caused by an inappropriate immune response directed against which of the following cells?

A. Astrocytes
B. Ependymal cells
C. Microglial cells
D. Oligodendrocytes
E. Schwann cells

Submit

A 35-year-old woman comes to the office due to trouble seeing out of her right eye. The patient started having blurry vision and pain with eye movement 2 days ago. She has no headache, vertigo, slurred speech, numbness, or weakness. Two years ago, the patient had an episode of double vision that spontaneously resolved after a few weeks. On physical examination, she has an afferent pupillary defect with markedly reduced visual acuity on the right. Funduscopy reveals blurring of the optic disk margins in the right eye. MRI of the brain reveals multiple, ovoid white matter lesions with perpendicular orientation to the lateral ventricles. This patient's condition is most likely caused by an inappropriate immune response directed against which of the following cells?

- A. Astrocytes (1%)
- B. Ependymal cells (4%)
- C. Microglial cells (1%)
- ✓ D. Oligodendrocytes (87%)
- E. Schwann cells (4%)

Omitted
Correct answer
D

87%
Answered correctly

01 sec
Time Spent

03/02/2020
Last Updated

Explanation

Pathogenesis of multiple sclerosis

Pathogenesis of multiple sclerosis

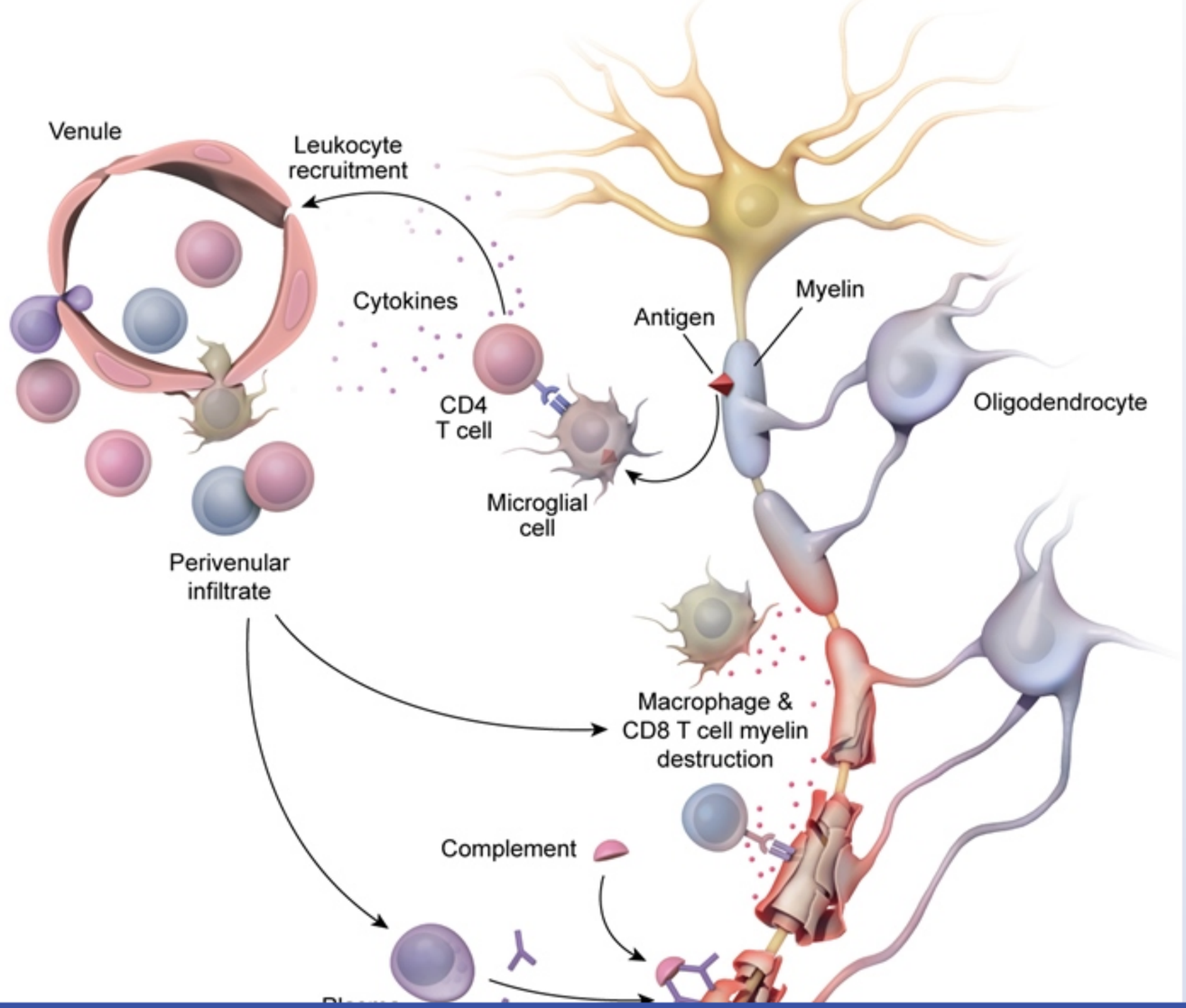

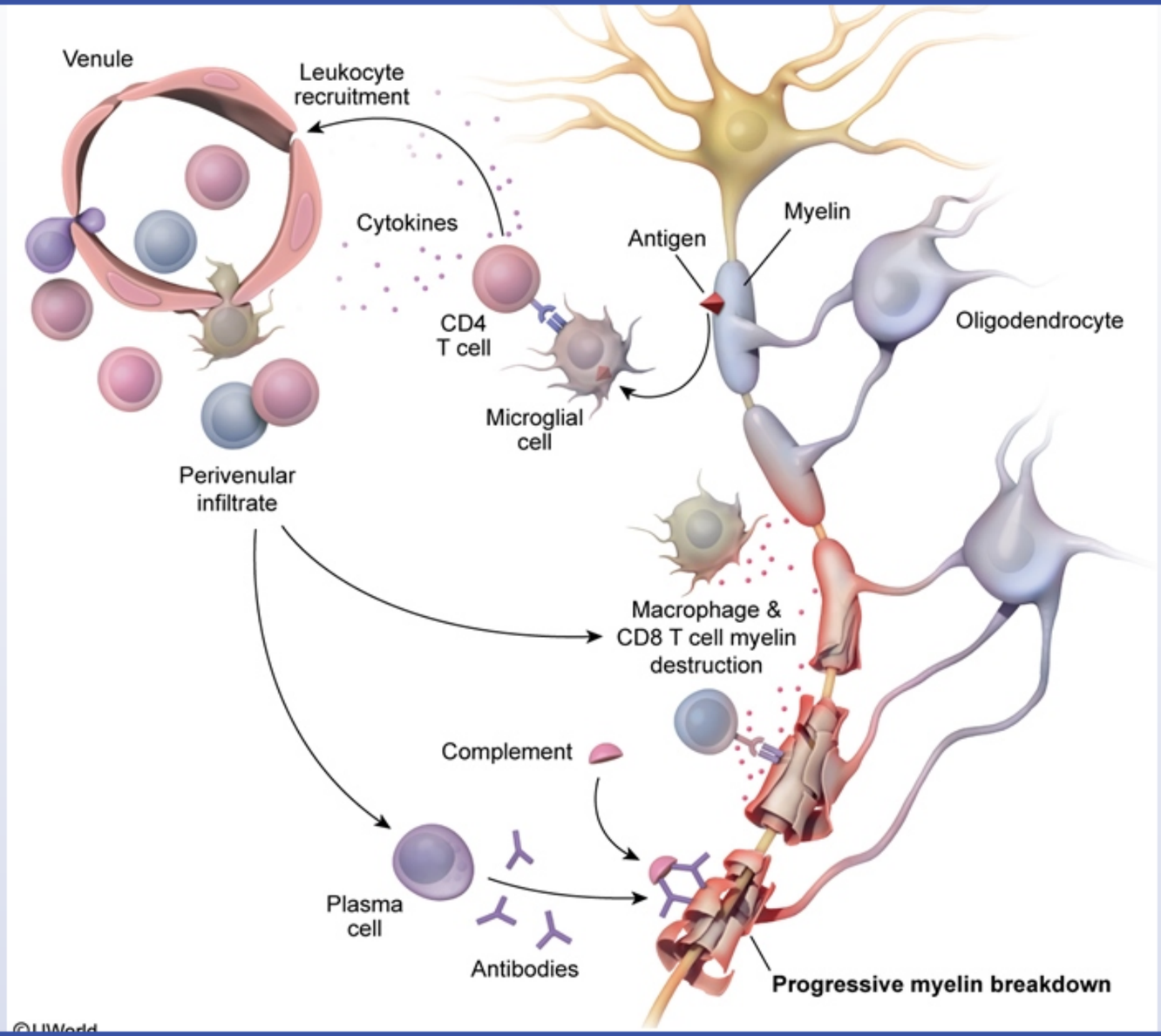
Venule
Leukocyte recruitment
Cytokines
CD4 T cell
Antigen
Myelin
Oligodendrocyte
Microglial cell
Perivenular infiltrate
Macrophage & CD8 T cell myelin destruction
Complement
Plasma cell
Antibodies
Progressive myelin breakdown

©UWorld

This patient likely has **multiple sclerosis** (MS), an autoimmune demyelinating disease of the central nervous system (CNS) that typically presents in young women (age <50) with **neurologic deficits** (eg, blurry vision, diplopia, focal weakness/numbness, dysarthria, bowel/bladder dysfunction) **disseminated in time and space**. A common initial manifestation of MS is **optic neuritis**, characterized by monocular visual loss with pain on eye movement and an afferent pupillary defect. MRI findings in MS typically include white matter lesions scattered throughout the brain and/or spinal cord with a predilection for the subcortical periventricular regions.

The pathogenesis of MS involves an autoimmune response targeting **oligodendrocytes**, the myelin-producing cells of the CNS. Helper T cells abnormally react to antigens in myelin, causing a release of inflammatory cytokines (eg, interferon-gamma) that promote the infiltration of destructive macrophages/microglia and leukocytes. B cells also play a role as most patients with MS have oligoclonal immunoglobulin bands in the cerebrospinal fluid. Myelin degeneration leads to slowed nerve conduction with neurologic deficits as described above.

(Choice A) Astrocytes are glial cells (non-neural cells) that contribute to the blood-brain barrier and play an important role in potassium buffering, neurotransmitter metabolism, and glial scar formation. Astrocytes proliferate and form the scar (gliosis) after the attack on oligodendrocytes; astrocytes are usually not targeted by the immunologic response in MS.

(Choice B) Ependymal cells are ciliated glial cells that line the ventricles of the brain and the central canal of the spinal cord. They also make up the choroid plexus and produce cerebrospinal fluid. These cells are not targeted by the immune response in MS.

(Choice C) Microglia function as the resident macrophages in the CNS. Although they participate in myelin destruction, they are not the target of the immune response in MS.

(Choice E) Schwann cells are the myelin-producing cells of the peripheral nervous system. These cells are targeted by the immunologic response associated with peripheral demyelinating disorders (eg, Guillain-Barré syndrome).

Educational objective:
The pathogenesis of multiple sclerosis involves an autoimmune response (T cell and antibody-mediated) targeting oligodendrocytes and myelin in the central nervous system, leading to slowed nerve conduction with neurologic deficits.

References

Exhibit Display

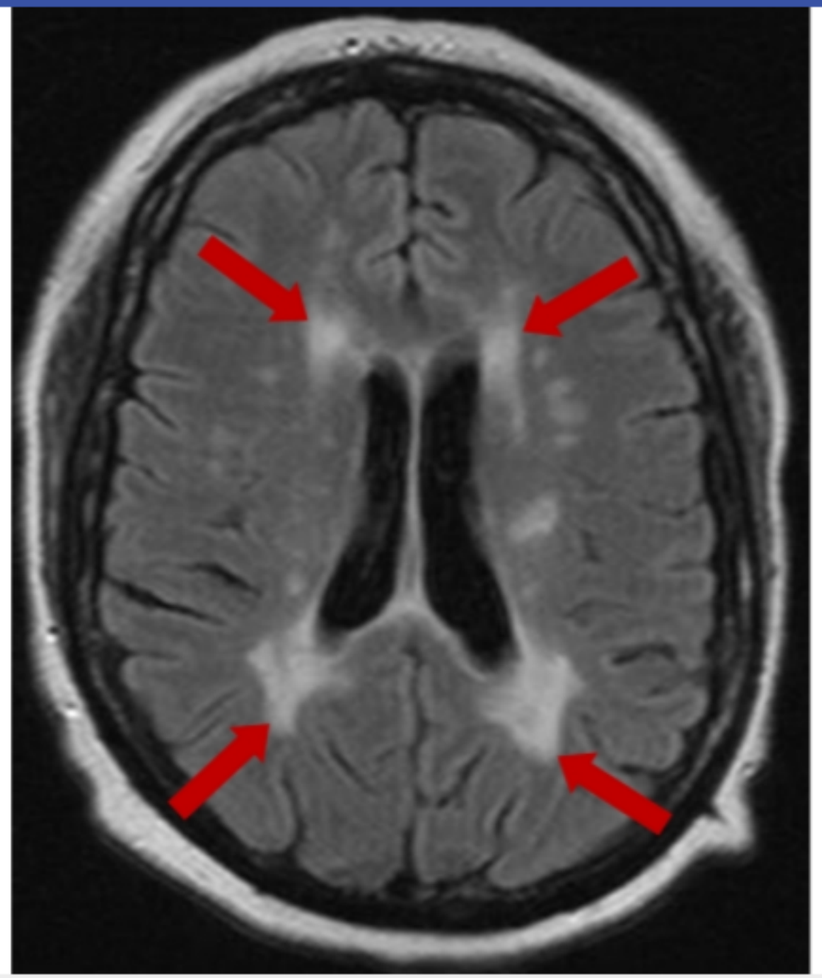

Zoom In
Zoom Out
Reset
Add To New Card | Existing Card

References

spinal cord with a predilection for the subcortical periventricular regions.

The pathogenesis of MS involves an autoimmune response targeting **oligodendrocytes**, the myelin-producing cells of the CNS. Helper T cells abnormally react to antigens in myelin, causing a release of inflammatory cytokines (eg, interferon-gamma) that promote the infiltration of destructive macrophages/microglia and leukocytes. B cells also play a role as most patients with MS have oligoclonal immunoglobulin bands in the cerebrospinal fluid. Myelin degeneration leads to slowed nerve conduction with neurologic deficits as described above.

(Choice A) Astrocytes are glial cells (non-neural cells) that contribute to the blood-brain barrier and play an important role in potassium buffering, neurotransmitter metabolism, and glial scar formation. Astrocytes proliferate and form the scar (gliosis) after the attack on oligodendrocytes; astrocytes are usually not targeted by the immunologic response in MS.

(Choice B) Ependymal cells are ciliated glial cells that line the ventricles of the brain and the central canal of the spinal cord. They also make up the choroid plexus and produce cerebrospinal fluid. These cells are not targeted by the immune response in MS.

(Choice C) Microglia function as the resident macrophages in the CNS. Although they participate in myelin destruction, they are not the target of the immune response in MS.

(Choice E) Schwann cells are the myelin-producing cells of the peripheral nervous system. These cells are targeted by the immunologic response associated with peripheral demyelinating disorders (eg, Guillain-Barré syndrome).

Educational objective:
The pathogenesis of multiple sclerosis involves an autoimmune response (T cell and antibody-mediated) targeting oligodendrocytes and myelin in the central nervous system, leading to slowed nerve conduction with neurologic deficits.

References

- Immunopathogenesis of multiple sclerosis.

Pathology	Nervous System	Multiple sclerosis
Subject	System	Topic

Copyright © UWorld. All rights reserved.

A researcher conducts a study to evaluate the morphological changes in various cerebral pathologies using live animal models. In an experiment, histopathological examination of the brain after an inciting event shows neurons with intensely eosinophilic cytoplasm and condensed basophilic nuclei. Serial biopsies are obtained to evaluate progressive changes. Which of the following is most likely to be seen in the affected brain area?

A. Extracellular amyloid deposition

B. Fibroblast migration

C. Glial cell hyperplasia

D. Neuronal hypertrophy

E. Vascular hyalinization

Submit

A researcher conducts a study to evaluate the morphological changes in various cerebral pathologies using live animal models. In an experiment, histopathological examination of the brain after an inciting event shows neurons with intensely eosinophilic cytoplasm and condensed basophilic nuclei. Serial biopsies are obtained to evaluate progressive changes. Which of the following is most likely to be seen in the affected brain area?

A. Extracellular amyloid deposition (9%)
B. Fibroblast migration (10%)
✓ C. Glial cell hyperplasia (59%)
D. Neuronal hypertrophy (9%)
E. Vascular hyalinization (10%)

Omitted
Correct answer
C

59%
Answered correctly

01 sec
Time Spent

01/25/2020
Last Updated

Explanation

Type of glial cell	Origin	Appearance	Functions
Astrocytes	Neuroectoderm	• Round vesicular nuclei • Contain glial fibrils, composed of glial fibrillary acidic protein	• Repair • Structural & metabolic support • Blood-brain barrier

Type of glial cell	Origin	Appearance	Functions
Astrocytes	Neuroectoderm	• Round vesicular nuclei • Contain glial fibrils, composed of glial fibrillary acidic protein	• Repair • Structural & metabolic support • Blood-brain barrier
Oligodendrocytes	Neuroectoderm	• Small nuclei surrounded by a pale halo • Fewer processes than astrocytes	• Production of myelin
Microglia	Primitive yolk sac macrophages	• Small elongated nuclei • Many short branching processes	• Phagocytosis

The histopathological findings of neurons with shrunken, basophilic nuclei and intensely eosinophilic cytoplasm (**red neurons**) are indicative of **irreversible neuronal damage**. In response to irreversible injury and neuronal death, astrocytes proliferate at the site of injury to restore tissue integrity (a role analogous to fibroblasts outside the CNS). This process is called astrocytosis (or **gliosis**) and is a universal response of the CNS to severe damage. As astrocytes proliferate, they replace lost neurons, compensate for their volume, and over time form a closely connected, firm meshwork called a **gliotic scar**.

(Choices A and E) Although both vascular hyalinization and amyloid deposition can lead to neural injury, both would show accumulations of *extracellular* eosinophilic material on histopathological examination.

(Choice B) Fibroblast migration to a site of injury occurs in most of the peripheral tissues of the body, but not the CNS, where tissue repair is a function of astrocytes.

Microglia	Primitive yolk sac macrophages	nuclei • Many short branching processes	• Phagocytosis

The histopathological findings of neurons with shrunken, basophilic nuclei and intensely eosinophilic cytoplasm (**red neurons**) are indicative of **irreversible neuronal damage**. In response to irreversible injury and neuronal death, astrocytes proliferate at the site of injury to restore tissue integrity (a role analogous to fibroblasts outside the CNS). This process is called astrocytosis (or **gliosis**) and is a universal response of the CNS to severe damage. As astrocytes proliferate, they replace lost neurons, compensate for their volume, and over time form a closely connected, firm meshwork called a **gliotic scar**.

(Choices A and E) Although both vascular hyalinization and amyloid deposition can lead to neural injury, both would show accumulations of *extracellular* eosinophilic material on histopathological examination.

(Choice B) Fibroblast migration to a site of injury occurs in most of the peripheral tissues of the body, but not the CNS, where tissue repair is a function of astrocytes.

(Choice D) Irreversibly injured neurons do not hypertrophy; they undergo cellular necrosis. Microglia are responsible for phagocytizing the resulting dead cells and debris.

Educational objective:
CNS injury is associated with astrocyte hypertrophy and proliferation (gliosis). This process leads to the formation of a glial scar, which compensates for the volume loss that occurs after neuronal death.

References

- Microglial cell origin and phenotypes in health and disease.

Pathology	Nervous System	Ischemic stroke
Subject	System	Topic

Copyright © UWorld. All rights reserved.

Microglia | Primitive yolk sac | nuclei | • Phagocytosis

Exhibit Display

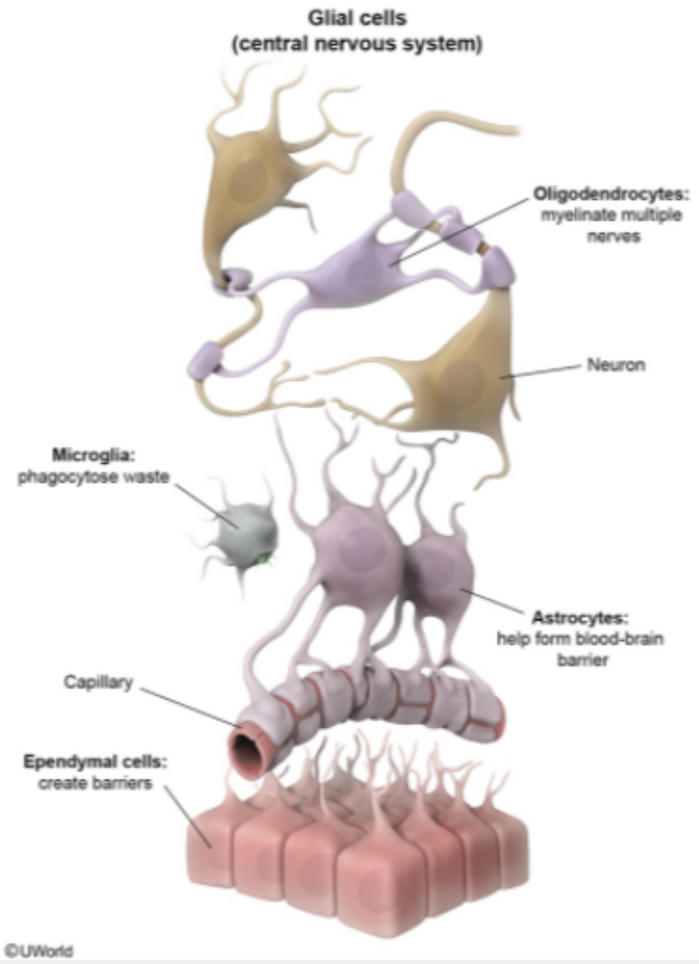

Zoom In | Zoom Out | Reset | Add To New Card | Existing Card

1
2
3
4
5
6
7
8
9
10
11
12
13
14
15
16
17
18
19

Microglia | Primitive yolk sac | nuclei | • Phagocytosis

Exhibit Display

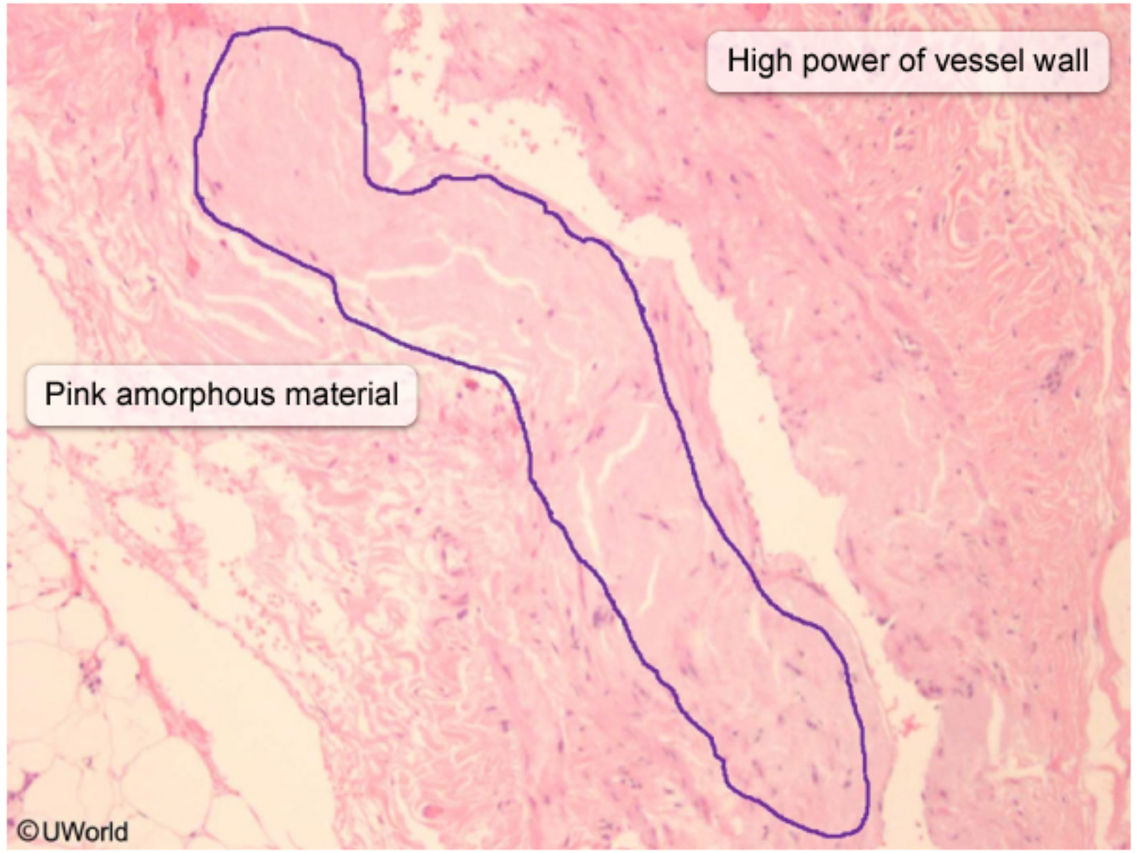

Zoom In | Zoom Out | Reset | Add To New Card | Existing Card

A 68-year-old man is brought to the emergency department by his daughter due to change in mental status. Over the past 2 days, the patient has started seeing strangers sneaking around the house despite only he and his daughter being at home. He has also been intermittently confused, difficult to rouse, and distractible. The patient has had no headaches or focal weakness. He has no history of psychiatric illness but has been taking a sleep aid due to insomnia for the past week. Temperature is 36.7 C (98 F), blood pressure is 140/85 mm Hg, pulse is 88/min, and respirations are 12/min. On physical examination, the patient is somnolent but rousable to voice. He is not oriented to place or time. Pupils are bilaterally equal and reactive to light. Bilateral upper and lower extremity muscle strength, deep tendon reflexes, and pain sensation are normal. Blood cell counts and serum chemistry studies are within normal limits. Which of the following is the most likely diagnosis?

- A. Acute ischemic stroke
- B. Brief psychotic disorder
- C. Dementia with Lewy bodies
- D. Frontotemporal dementia
- E. Medication-induced delirium
- F. Occult bacterial infection

Submit

A 68-year-old man is brought to the emergency department by his daughter due to change in mental status. Over the past 2 days, the patient has started seeing strangers sneaking around the house despite only he and his daughter being at home. He has also been intermittently confused, difficult to rouse, and distractible. The patient has had no headaches or focal weakness. He has no history of psychiatric illness but has been taking a sleep aid due to insomnia for the past week. Temperature is 36.7 C (98 F), blood pressure is 140/85 mm Hg, pulse is 88/min, and respirations are 12/min. On physical examination, the patient is somnolent but rousable to voice. He is not oriented to place or time. Pupils are bilaterally equal and reactive to light. Bilateral upper and lower extremity muscle strength, deep tendon reflexes, and pain sensation are normal. Blood cell counts and serum chemistry studies are within normal limits. Which of the following is the most likely diagnosis?

- A. Acute ischemic stroke (0%)
- B. Brief psychotic disorder (3%)
- C. Dementia with Lewy bodies (10%)
- D. Frontotemporal dementia (2%)
- ✓ E. Medication-induced delirium (81%)
- F. Occult bacterial infection (1%)

Omitted
Correct answer
E

81%
Answered correctly

02 secs
Time Spent

02/27/2020
Last Updated

Explanation

This patient's acute onset of fluctuating altered mental status (eg, impaired attention, change in level of consciousness, hallucinations,

Explanation

This patient's acute onset of fluctuating altered mental status (eg, impaired attention, change in level of consciousness, hallucinations, disorientation) in the context of recent initiation of a sleep aid is consistent with **medication-induced delirium**. Delirium is a disorder of attention and general cognition that has an **acute onset** and follows a **fluctuating course**. Delirium is frequently multifactorial and is most commonly caused by an acute medical illness, adverse effect of a medication, or drug intoxication/withdrawal.

Elderly patients are at **increased risk** for delirium, and medications with a high risk of precipitating delirium (eg, sedative-hypnotics [eg, zolpidem], benzodiazepines, opioids, anticholinergic agents) must be used with extreme caution in this patient population. Elderly patients with baseline dementia are even more vulnerable to delirium. The definitive treatment for delirium involves addressing the underlying cause (eg, treating the medical illness, removing the offending medication).

(Choice A) Acute ischemic stroke rarely causes acute delirium, especially without the presence of focal neurological deficits.

(Choice B) Brief psychotic disorder may be diagnosed in patients with ≥1 day but <1 month of psychotic symptoms (which are not better explained by the effects of a medication or medical illness). Patients with brief psychotic disorder are typically fully oriented.

(Choice C) Dementia with Lewy bodies is a neurodegenerative disorder characterized by progressive dementia, fluctuating cognition, parkinsonian symptoms, REM sleep behavior disorder, and visual hallucinations.

(Choice D) Frontotemporal dementia is a progressive neurodegenerative disease that classically presents with early and prominent behavioral disturbances (eg, impulsivity, disinhibition, apathy) with subsequent progressive decline in executive function, memory, and language function.

(Choice F) Although an occult bacterial infection may precipitate delirium, this patient's normal laboratory results, vital signs, and physical examination; absence of systemic symptoms; and recent initiation of a drug known to cause delirium make medication-induced delirium a better explanation for his symptoms.

Educational objective:
Delirium is characterized by the acute onset of fluctuating disturbance in attention and general cognition (eg, altered level of consciousness, disorientation, hallucinations). Common medications that may precipitate delirium in high-risk populations (eg, elderly patients) include sedative-hypnotics, benzodiazepines, opioids, and anticholinergic medications.

treating the medical illness, removing the offending medication).

(Choice A) Acute ischemic stroke rarely causes acute delirium, especially without the presence of focal neurological deficits.

(Choice B) Brief psychotic disorder may be diagnosed in patients with ≥1 day but <1 month of psychotic symptoms (which are not better explained by the effects of a medication or medical illness). Patients with brief psychotic disorder are typically fully oriented.

(Choice C) Dementia with Lewy bodies is a neurodegenerative disorder characterized by progressive dementia, fluctuating cognition, parkinsonian symptoms, REM sleep behavior disorder, and visual hallucinations.

(Choice D) Frontotemporal dementia is a progressive neurodegenerative disease that classically presents with early and prominent behavioral disturbances (eg, impulsivity, disinhibition, apathy) with subsequent progressive decline in executive function, memory, and language function.

(Choice F) Although an occult bacterial infection may precipitate delirium, this patient's normal laboratory results, vital signs, and physical examination; absence of systemic symptoms; and recent initiation of a drug known to cause delirium make medication-induced delirium a better explanation for his symptoms.

Educational objective:
Delirium is characterized by the acute onset of fluctuating disturbance in attention and general cognition (eg, altered level of consciousness, disorientation, hallucinations). Common medications that may precipitate delirium in high-risk populations (eg, elderly patients) include sedative-hypnotics, benzodiazepines, opioids, and anticholinergic medications.

References

- Managing delirium in the emergency department: tools for targeting underlying etiology.
- Delirium in older persons: advances in diagnosis and treatment.

Pathology	Nervous System	Delirium
Subject	System	Topic

Copyright © UWorld. All rights reserved.

A Caucasian male who suffers from a severe neurological disease dies of an overwhelming respiratory infection. Autopsy shows an atrophic precentral gyrus and thin anterior roots of the spinal cord. Light microscopy reveals a severe loss of neurons in the anterior horn of the spinal cord and in the hypoglossal and ambiguous cranial nerve nuclei; corticospinal tracts stain only faintly, indicating demyelinization. The patient most likely suffered from which of the following?

A. Amyotrophic lateral sclerosis
B. Poliomyelitis
C. Rabies
D. Huntington disease
E. Friedreich ataxia
F. Vitamin B_{12} deficiency

Submit

A Caucasian male who suffers from a severe neurological disease dies of an overwhelming respiratory infection. Autopsy shows an atrophic precentral gyrus and thin anterior roots of the spinal cord. Light microscopy reveals a severe loss of neurons in the anterior horn of the spinal cord and in the hypoglossal and ambiguous cranial nerve nuclei; corticospinal tracts stain only faintly, indicating demyelinization. The patient most likely suffered from which of the following?

- ✓ A. Amyotrophic lateral sclerosis (69%)
- B. Poliomyelitis (17%)
- C. Rabies (2%)
- D. Huntington disease (1%)
- E. Friedreich ataxia (4%)
- F. Vitamin B_{12} deficiency (3%)

Omitted
Correct answer
A

69%
Answered correctly

01 sec
Time Spent

02/27/2020
Last Updated

Explanation

Amyotrophic lateral sclerosis (ALS) is the most common motor neuron disease. Combined upper motor neuron (UMN) and lower motor neuron (LMN) lesions are characteristic: damage to motor neurons of the anterior horns (LMN lesion) and demyelination of the corticospinal tracts (UMN lesion) are present. The result is denervation atrophy of the muscles (amyotrophy). The disease manifests in middle-aged people and has a progressive course. Most patients die within 5 years of diagnosis. Respiratory complications (such as aspiration pneumonia) are the most

Amyotrophic lateral sclerosis (ALS) is the most common motor neuron disease. Combined upper motor neuron (UMN) and lower motor neuron (LMN) lesions are characteristic: damage to motor neurons of the anterior horns (LMN lesion) and demyelination of the corticospinal tracts (UMN lesion) are present. The result is denervation atrophy of the muscles (amyotrophy). The disease manifests in middle-aged people and has a progressive course. Most patients die within 5 years of diagnosis. Respiratory complications (such as aspiration pneumonia) are the most common cause of death. Important information about ALS is summarized in the table below.

Criteria	Description
Macroscopic	Thin anterior roots Mild atrophy of the precentral gyrus
Microscopic	Loss of neurons in the **anterior horn** (LMN lesion) Degeneration and atrophy of the **lateral corticospinal tracts** (UMN lesion) Loss of neurons in the motor nuclei of CN V, IX, X, XII Muscle: denervation atrophy (small angular fibers)
Clinical	LMN symptoms: muscle weakness, atrophy, and fasciculation UMN symptoms: spasticity, hyperreflexia, and pathologic reflexes
Genetic	Mutation of the gene that codes for copper-zinc superoxide dismutase (SOD1) may be implicated
Treatment	Riluzole MOA: decreases glutamate release

(Choice B) Poliomyelitis is an enteroviral infection that damages motor neurons of the anterior horns. It is a pure lower motor neuron (LMN) disease. Clinical features include flaccid paralysis, atrophy, areflexia, and fasciculation.

(Choice C) The prodromal phase of rabies infection is characterized by fever, pharyngitis, and pain around the bite site. Acute encephalitis

	UMN symptoms: spasticity, hyperreflexia, and pathologic reflexes
Genetic	Mutation of the gene that codes for copper-zinc superoxide dismutase (SOD1) may be implicated
Treatment	Riluzole MOA: decreases glutamate release

(Choice B) Poliomyelitis is an enteroviral infection that damages motor neurons of the anterior horns. It is a pure lower motor neuron (LMN) disease. Clinical features include flaccid paralysis, atrophy, areflexia, and fasciculation.

(Choice C) The prodromal phase of rabies infection is characterized by fever, pharyngitis, and pain around the bite site. Acute encephalitis develops later. Ultimately, paralysis, confusion or hyperactivity, focal neurologic deficits, and coma occur.

(Choice D) Huntington disease is an autosomal dominant disorder that leads to atrophy of the caudate nucleus and putamen. It causes progressive dementia, behavioral changes, and choreiform movements.

(Choice E) Friedrich ataxia is an autosomal recessive disorder that manifests in children 5-15 years old. The main symptom is difficulty walking (ataxia). This disease is associated with hypertrophic cardiomyopathy, kyphoscoliosis, foot abnormalities, and diabetes mellitus.

(Choice F) Vitamin B 12 deficiency causes subacute combined degeneration of the dorsal (posterior) and lateral spinal columns.

Educational objective:
Amyotrophic lateral sclerosis (ALS) causes both upper and lower motor neuron lesions. Loss of neurons of the anterior horns of the spinal cord (LMN lesion) causes muscle weakness and atrophy. Demyelination of the lateral corticospinal tract (UMN lesion) leads to spasticity and hyperreflexia.

Pathology	Nervous System	Amyotrophic lateral sclerosis
Subject	System	Topic

Copyright © UWorld. All rights reserved.

A 52-year-old man is brought to the office due to social withdrawal and inability to care for himself. The patient is divorced and lives alone, and he was found to be living in disarray by his daughter, who is visiting from out of state. His neighbors and friends say the patient rarely comes out of the house or contacts them. During previous visits, his daughter noticed fidgety movements of his hands, but now he has marked jerky movements of his extremities with frequent facial grimaces. He has a history of depression with frequent angry outbursts that led to his divorce several years ago. The patient has no other medical conditions and does not use tobacco, alcohol, or illicit drugs. He was adopted and his family history is unknown. On physical examination, the patient is forgetful and has slowed mental processing. Involuntary, spasmodic movements of the hands and facial muscles are present. Deep tendon reflexes and sensation are normal. The loss of neurons supplying which of the following neurotransmitters is most specific for this patient's disease process?

A. Acetylcholine
B. Dopamine
C. GABA
D. Norepinephrine
E. Serotonin

Submit

A 52-year-old man is brought to the office due to social withdrawal and inability to care for himself. The patient is divorced and lives alone, and he was found to be living in disarray by his daughter, who is visiting from out of state. His neighbors and friends say the patient rarely comes out of the house or contacts them. During previous visits, his daughter noticed fidgety movements of his hands, but now he has marked jerky movements of his extremities with frequent facial grimaces. He has a history of depression with frequent angry outbursts that led to his divorce several years ago. The patient has no other medical conditions and does not use tobacco, alcohol, or illicit drugs. He was adopted and his family history is unknown. On physical examination, the patient is forgetful and has slowed mental processing. Involuntary, spasmodic movements of the hands and facial muscles are present. Deep tendon reflexes and sensation are normal. The loss of neurons supplying which of the following neurotransmitters is most specific for this patient's disease process?

- A. Acetylcholine (13%)
- B. Dopamine (24%)
- ✓ C. GABA (60%)
- D. Norepinephrine (0%)
- E. Serotonin (0%)

Omitted
Correct answer
C

60%
Answered correctly

01 sec
Time Spent

03/30/2020
Last Updated

Explanation

This patient with behavioral abnormalities (eg, mood changes, withdrawal), cognitive impairment, and chorea (eg, jerky, fidgety, involuntary movements) most likely has **Huntington disease** (HD). HD is a neurodegenerative disorder inherited as an autosomal dominant trait and

This patient with behavioral abnormalities (eg, mood changes, withdrawal), cognitive impairment, and chorea (eg, jerky, fidgety, involuntary movements) most likely has **Huntington disease** (HD). HD is a neurodegenerative disorder inherited as an autosomal dominant trait and classically manifests between ages 30 and 50. Excessive **CAG trinucleotide repeats** cause a gain-of-function mutation that leads to the accumulation of abnormal huntingtin protein in neural cells.

The **inhibitory GABAergic neurons** in the caudate nuclei **(striatum)** are especially vulnerable and **atrophy** early in the course of the disease. These neurons play an important role in regulating both emotional and motor impulses from the cerebral cortex, and their loss is central to the behavioral and movement changes in HD. As HD progresses, neuronal atrophy becomes more widespread. Patients display features of advanced dementia (eg, memory loss, facial agnosia, incontinence) with bradykinesia and near-total absence of voluntary movement.

(Choice A) The largest concentration of acetylcholine-producing neurons in the brain is found in the amygdala (eg, nucleus basalis of Meynert). Although there are lower levels of acetylcholine in the amygdalas of patients with HD, this change is not specific to the disease (it also occurs in Alzheimer and Lewy body dementia), and atrophy of these neurons does not occur until late in the clinical course.

(Choice B) In HD, dopamine is typically increased, likely due to the loss of regulation by inhibitory GABA-producing neurons. Loss of dopaminergic neurons in the substantia nigra and striatum is found in Parkinson disease.

(Choices D and E) Reduced concentrations of norepinephrine and serotonin in the CNS are associated with depression, which can be treated with agents (eg, SSRIs, SNRIs) that block the reuptake or degradation of these neurotransmitters.

Educational objective:
Huntington disease is an autosomal dominant neurodegenerative disease that leads to the accumulation of abnormal, toxic huntingtin protein in neural cells. Inhibitory GABAergic neurons in the caudate nuclei are most susceptible, and their loss is responsible for the characteristic manifestations of Huntington disease (eg, chorea, behavioral abnormalities).

Pathology	Nervous System	Huntington disease
Subject	System	Topic

Copyright © UWorld. All rights reserved.

A 43-year-old woman is brought to the emergency department because of a sudden and severe headache. Her blood pressure is 160/90 mm Hg and pulse is 90/min. Her pupils are symmetric and reactive to light and she can move all four extremities without weakness. CT of her head is shown below.

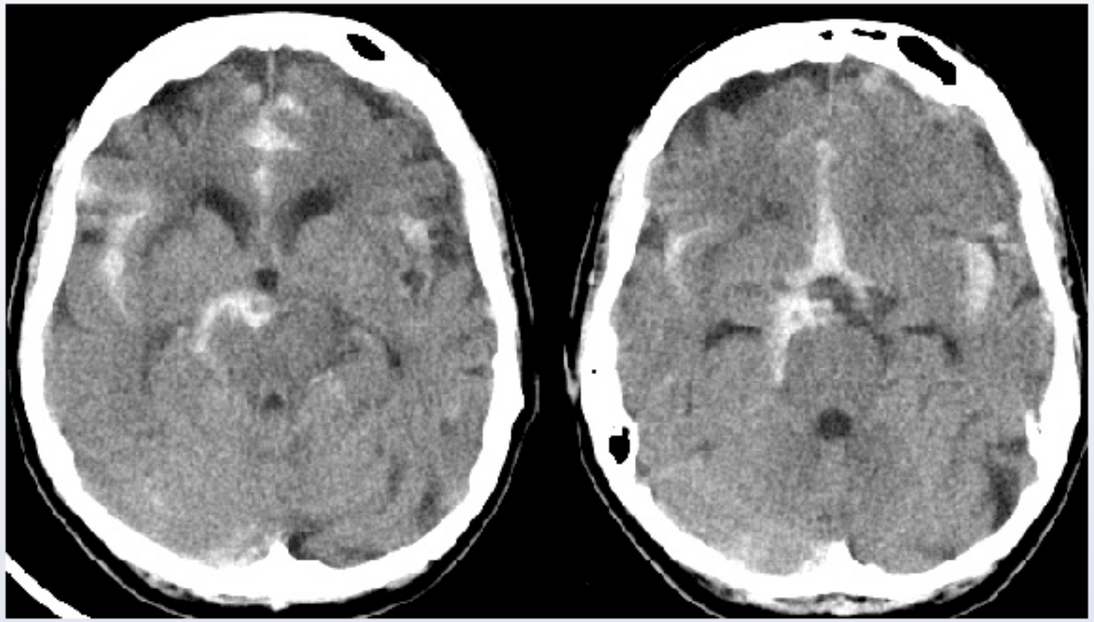

This patient's condition is most likely caused by which of the following?

A. Carotid artery atherosclerosis

B. Cardiac embolism

C. Hypoxic encephalopathy

D. Hypertensive encephalopathy

E. Large vessel arteritis

1
2
3
4
5
6
7
8
9
10
11
12
13
14
15
16
17
18
19

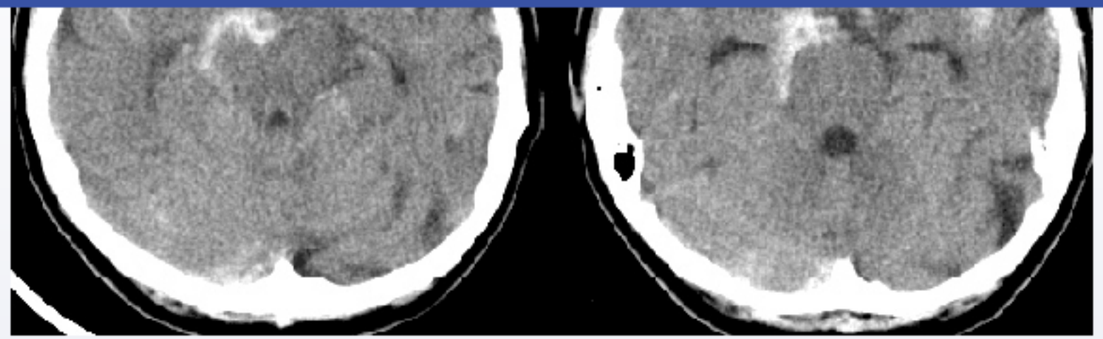

This patient's condition is most likely caused by which of the following?

- A. Carotid artery atherosclerosis
- B. Cardiac embolism
- C. Hypoxic encephalopathy
- D. Hypertensive encephalopathy
- E. Large vessel arteritis
- F. Hypertensive arteriolar sclerosis
- G. Cerebral amyloid angiopathy
- H. Rupture of saccular aneurysm
- I. Charcot-Bouchard aneurysm

Submit

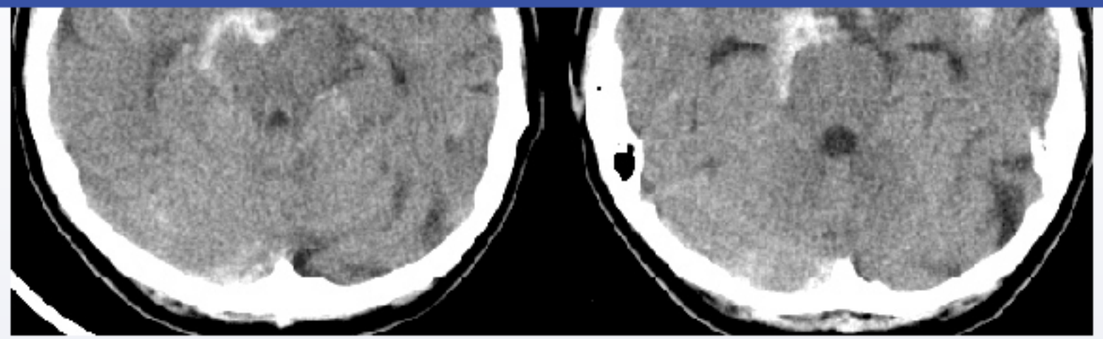

This patient's condition is most likely caused by which of the following?

- A. Carotid artery atherosclerosis (1%)
- B. Cardiac embolism (0%)
- C. Hypoxic encephalopathy (1%)
- D. Hypertensive encephalopathy (10%)
- E. Large vessel arteritis (2%)
- F. Hypertensive arteriolar sclerosis (5%)
- G. Cerebral amyloid angiopathy (2%)
- ✓ H. Rupture of saccular aneurysm (62%)
- I. Charcot-Bouchard aneurysm (13%)

Omitted
Correct answer

62%
Answered correctly

04 secs
Time Spent

04/11/2020
Last Updated

Explanation

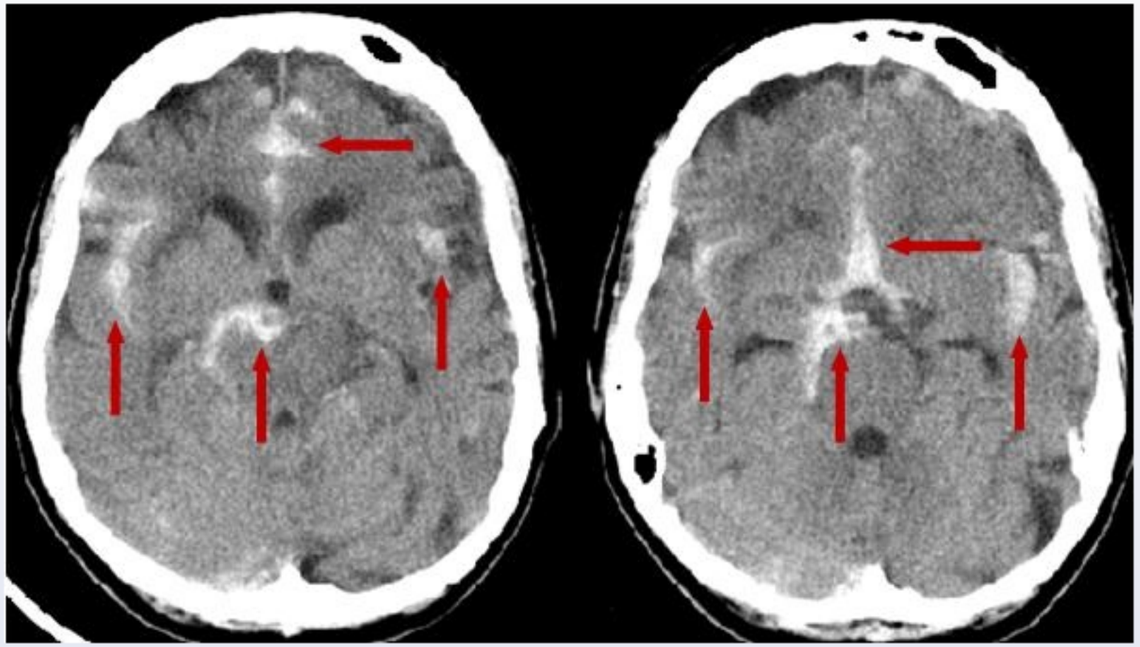

Clinically, the abrupt onset of a severe headache is very characteristic of subarachnoid hemorrhage (SAH), and the above non-contrast CT scan confirms this diagnosis (note the hyperdensity seen within the cisterns/sulci, arrows). The generalized, severe headache of SAH is often described by patients as "the worst headache of my life." Fever and nuchal rigidity may also be present. Focal neurological deficits are usually not present.

Saccular (berry) aneurysms are the most common cause of SAH. These aneurysms usually occur at the circle of Willis, with the anterior communicating artery being the most common site. Berry aneurysms are associated with Ehlers-Danlos syndrome and autosomal dominant polycystic kidney disease. Arteriovenous malformations also predispose certain individuals to SAH.

In SAH, blood accumulates between the arachnoid and pia mater. A CT scan without contrast is diagnostic. Lumbar puncture reveals gross blood or xanthochromia (yellow discoloration of cerebrospinal fluid).

Clinically, the abrupt onset of a severe headache is very characteristic of subarachnoid hemorrhage (SAH), and the above non-contrast CT scan confirms this diagnosis (note the hyperdensity seen within the cisterns/sulci, arrows). The generalized, severe headache of SAH is often described by patients as "the worst headache of my life." Fever and nuchal rigidity may also be present. Focal neurological deficits are usually not present.

Saccular (berry) aneurysms are the most common cause of SAH. These aneurysms usually occur at the circle of Willis, with the anterior communicating artery being the most common site. Berry aneurysms are associated with Ehlers-Danlos syndrome and autosomal dominant polycystic kidney disease. Arteriovenous malformations also predispose certain individuals to SAH.

In SAH, blood accumulates between the arachnoid and pia mater. A CT scan without contrast is diagnostic. Lumbar puncture reveals gross blood or xanthochromia (yellow discoloration of cerebrospinal fluid).

(Choice G) Cerebral amyloid angiopathy occurs in elderly patients. It may be asymptomatic or may lead to recurrent intracerebral hemorrhage. These bleeds usually affect small areas of the cerebral hemispheres and present with headache and focal neurologic deficits (i.e., paresis, sensory loss, etc).

(Choice I) Charcot-Bouchard aneurysms are small in size (< 1 mm in diameter) and occur in patients with long-standing hypertension. They are found in the arterioles that supply the basal ganglia, internal capsule, and deep white matter. Charcot-Bouchard aneurysms can rupture and cause intracerebral hemorrhage, not SAH.

Educational objective:
Subarachnoid hemorrhage presents with a generalized, excruciating headache. It is classically described by patients as "the worst headache of my life." Subarachnoid hemorrhage usually occurs due to rupture of saccular (berry) aneurysms or arteriovenous malformations. Berry aneurysms of the circle of Willis are associated with autosomal dominant polycystic kidney disease.

Pathology	Nervous System	Subarachnoid hemorrhage
Subject	System	Topic

Copyright © UWorld. All rights reserved.

Clinically, the abrupt onset of a severe headache is very characteristic of subarachnoid hemorrhage (SAH), and the above non-contrast CT scan confirms this diagnosis (note the hyperdensity seen within the cisterns/sulci, arrows). The generalized, severe headache of SAH is often described by patients as "the worst headache of my life." Fever and nuchal rigidity may also be present. Focal neurological deficits are usually not present.

Saccular (berry) aneurysms are the most common cause of SAH. These aneurysms usually occur at the circle of Willis, with the anterior communicating artery being the most common site. Berry aneurysms are associated with Ehlers-Danlos syndrome and autosomal dominant polycystic kidney disease. Arteriovenous malformations also predispose certain individuals to SAH.

In SAH, blood accumulates between the arachnoid and pia mater. A CT scan without contrast is diagnostic. Lumbar puncture reveals gross blood or xanthochromia (yellow discoloration of cerebrospinal fluid).

(Choice G) Cerebral amyloid angiopathy occurs in elderly patients. It may be asymptomatic or may lead to recurrent intracerebral hemorrhage. These bleeds usually affect small areas of the cerebral hemispheres and present with headache and focal neurologic deficits (i.e., paresis, sensory loss, etc).

(Choice I) Charcot-Bouchard aneurysms are small in size (< 1 mm in diameter) and occur in patients with long-standing hypertension. They are found in the arterioles that supply the basal ganglia, internal capsule, and deep white matter. Charcot-Bouchard aneurysms can rupture and cause intracerebral hemorrhage, not SAH.

Educational objective:
Subarachnoid hemorrhage presents with a generalized, excruciating headache. It is classically described by patients as "the worst headache of my life." Subarachnoid hemorrhage usually occurs due to rupture of saccular (berry) aneurysms or arteriovenous malformations. Berry aneurysms of the circle of Willis are associated with autosomal dominant polycystic kidney disease.

Pathology	Nervous System	Subarachnoid hemorrhage
Subject	System	Topic

Copyright © UWorld. All rights reserved.

1
2
3
4
5
6
7
8
9
10
11
12
13
14
15
16
17
18
19

A 45-year-old woman is brought to the emergency department after an episode during which she abruptly lost consciousness and had rhythmic jerking movements of the limbs followed by a period of confusion. The patient has had mild daily headaches associated with nausea that have progressed over the past 2 years. The headaches are worse at night and occasionally awaken her. The patient reports no head trauma, visual changes, weakness, numbness, or difficulty swallowing or speaking. She does not use alcohol or illicit drugs. There is no family history of seizures. An intracranial mass is discovered on neuroimaging and a biopsy of the mass is shown in the image below.

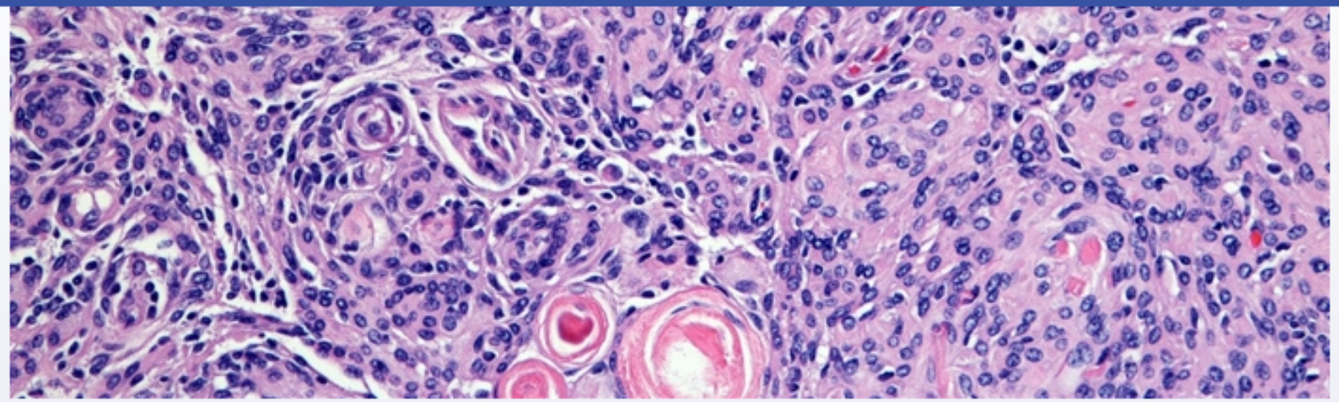

Which of the following is the most likely diagnosis?

- A. Craniopharyngioma
- B. Ependymoma
- C. Glioblastoma
- D. Medulloblastoma
- E. Meningioma
- F. Oligodendroglioma
- G. Pilocytic astrocytoma
- H. Schwannoma

Submit

1
2
3
4
5
6
7
8
9
10
11
12
13
14
15
16
17
18
19

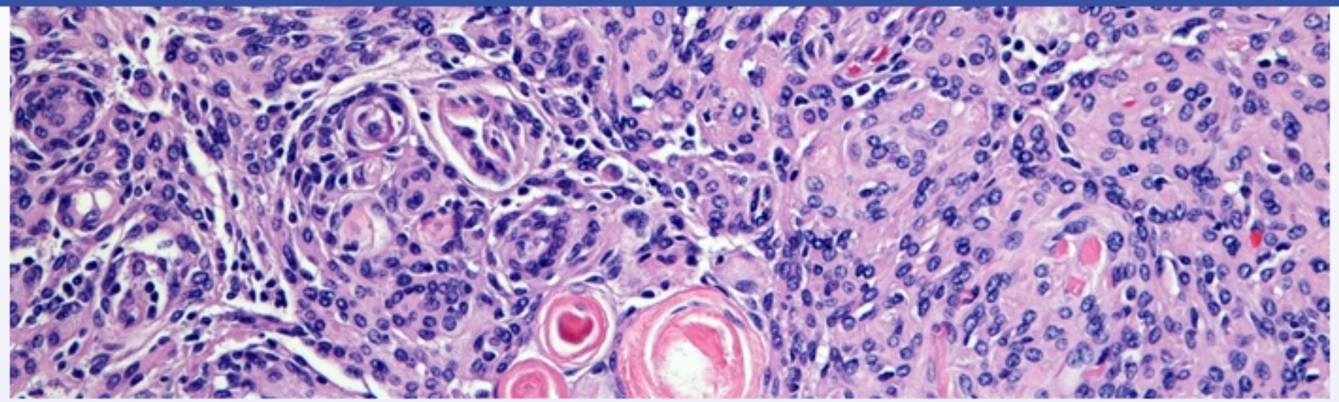

Which of the following is the most likely diagnosis?

- A. Craniopharyngioma (1%)
- B. Ependymoma (2%)
- C. Glioblastoma (11%)
- D. Medulloblastoma (4%)
- ✓ E. Meningioma (68%)
- F. Oligodendroglioma (5%)
- G. Pilocytic astrocytoma (2%)
- H. Schwannoma (2%)

Omitted
Correct answer

68%
Answered correctly

04 secs
Time Spent

03/03/2020
Last Updated

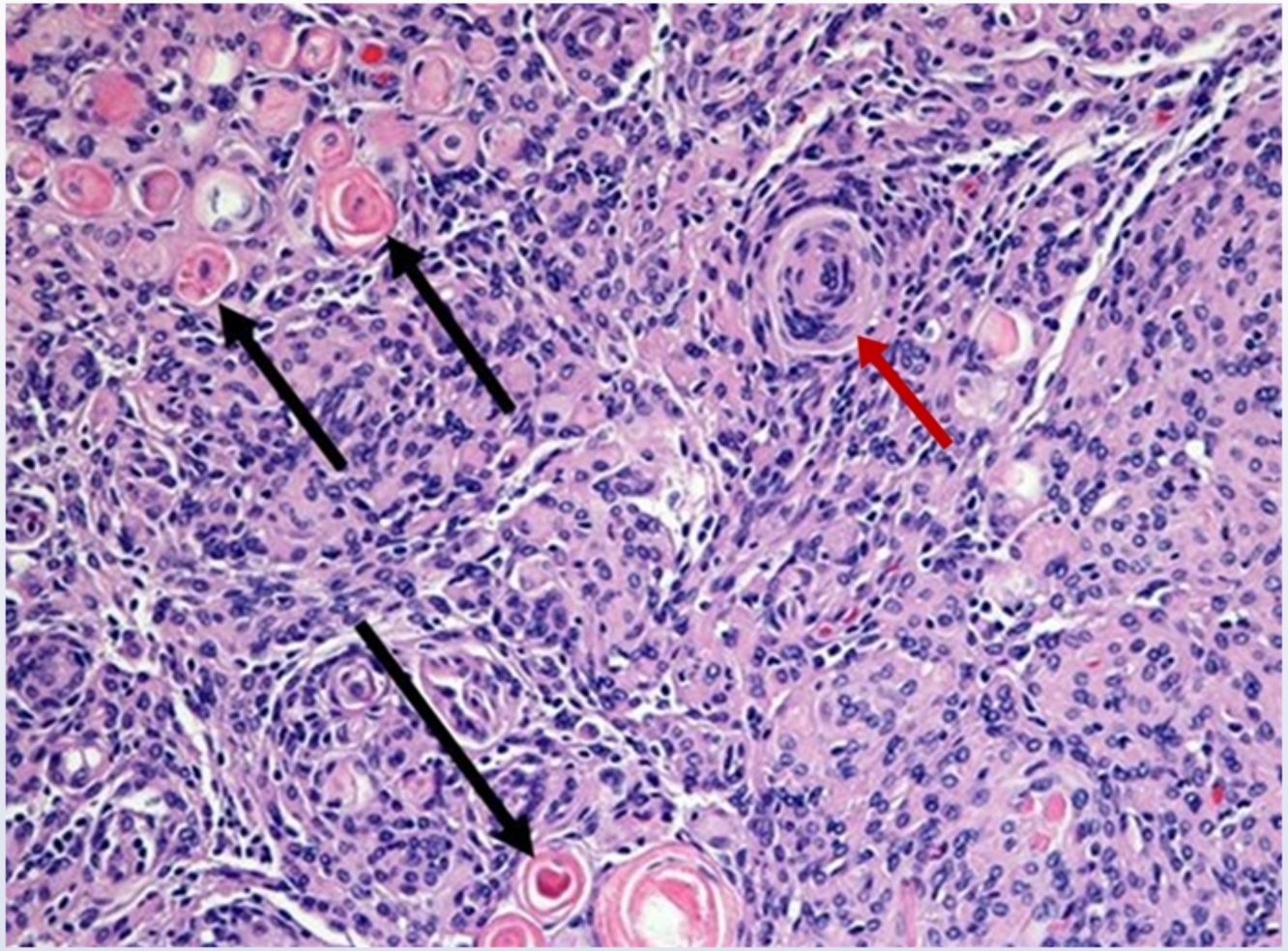

This patient's biopsy findings are consistent with **meningioma**, a slow-growing benign tumor derived from meningothelial cells of the arachnoid. Note the whorled pattern (red arrow) of cellular growth that forms syncytial nests, which may calcify and appear as round, eosinophilic laminar structures called psammoma bodies (black arrows). Other examples of tumors that form psammoma bodies include papillary thyroid carcinoma, mesothelioma, and papillary serous carcinoma of the ovary and endometrium.

This patient's biopsy findings are consistent with **meningioma**, a slow-growing benign tumor derived from meningothelial cells of the arachnoid. Note the whorled pattern (red arrow) of cellular growth that forms syncytial nests, which may calcify and appear as round, eosinophilic laminar structures called psammoma bodies (black arrows). Other examples of tumors that form psammoma bodies include papillary thyroid carcinoma, mesothelioma, and papillary serous carcinoma of the ovary and endometrium.

Meningiomas form well-circumscribed, round masses attached to the dura and are commonly found at the falcine, parasagittal, or lateral convexity regions of the brain. **Seizure** can occur due to compression of the adjacent cerebral cortex. Headaches, nausea, and vomiting may result from increased intracranial pressure, which worsens during recumbency and with sleep (due to increased intracranial blood volume). Individuals may also develop focal neurologic deficits depending on tumor size/location.

(Choice A) Adamantinomatous craniopharyngiomas most often present as benign suprasellar tumors in children and appear as cords/nests of palisading squamous epithelium with internal areas of lamellar "wet" keratin under light microscopy.

(Choice B) Ependymomas typically present as paraventricular tumors (eg, floor of the fourth ventricle) and have characteristic perivascular rosettes under light microscopy.

(Choice C) Glioblastomas are the most common primary malignant brain tumor in adults. They are often located in the cerebral hemispheres and may cross the corpus callosum ("butterfly glioma"). Light microscopy shows hypercellular areas of atypical astrocytes bordering regions of necrosis (pseudo-palisading).

(Choice D) Medulloblastomas are malignant cerebellar tumors that typically occur in children and are characterized by small blue cells that may surround neuropil, forming Homer-Wright rosettes under light microscopy.

(Choice F) Oligodendrogliomas typically involve the white matter of the cerebral hemispheres, and tumor cells have a "fried egg" appearance (round nuclei surrounded by a halo of clear cytoplasm) under light microscopy.

(Choice G) Pilocytic astrocytomas are usually benign tumors that involve the cerebellum in children and young adults. Tumor cells typically have eosinophilic granular bodies and elongated hairlike processes (Rosenthal fibers) under light microscopy.

(Choice H) Schwannomas are mostly benign tumors that commonly arise from the vestibular branch of cranial nerve VIII at the cerebellopontine angle. Light microscopy typically shows spindle cells with palisading nuclei arranged around Verocay bodies composed of eosinophilic cores

rosettes under light microscopy.

(Choice C) Glioblastomas are the most common primary malignant brain tumor in adults. They are often located in the cerebral hemispheres and may cross the corpus callosum ("butterfly glioma"). Light microscopy shows hypercellular areas of atypical astrocytes bordering regions of necrosis (pseudo-palisading).

(Choice D) Medulloblastomas are malignant cerebellar tumors that typically occur in children and are characterized by small blue cells that may surround neuropil, forming Homer-Wright rosettes under light microscopy.

(Choice F) Oligodendrogliomas typically involve the white matter of the cerebral hemispheres, and tumor cells have a "fried egg" appearance (round nuclei surrounded by a halo of clear cytoplasm) under light microscopy.

(Choice G) Pilocytic astrocytomas are usually benign tumors that involve the cerebellum in children and young adults. Tumor cells typically have eosinophilic granular bodies and elongated hairlike processes (Rosenthal fibers) under light microscopy.

(Choice H) Schwannomas are mostly benign tumors that commonly arise from the vestibular branch of cranial nerve VIII at the cerebellopontine angle. Light microscopy typically shows spindle cells with palisading nuclei arranged around Verocay bodies composed of eosinophilic cores (Antoni A pattern).

Educational objective:
Meningiomas are slow-growing, well-circumscribed, benign intracranial tumors typically found at the cerebral convexities in adults. Characteristic histopathologic features include a whorled pattern of cellular growth that forms nests, which may calcify into round, eosinophilic laminar structures called psammoma bodies.

References

- Review of meningioma histopathology.

Pathology	Nervous System	Brain tumors
Subject	System	Topic

Copyright © UWorld. All rights reserved.

1
2
3
4
5
6
7
8
9
10
11
12
13
14
15
16
17
18
19

Exhibit Display

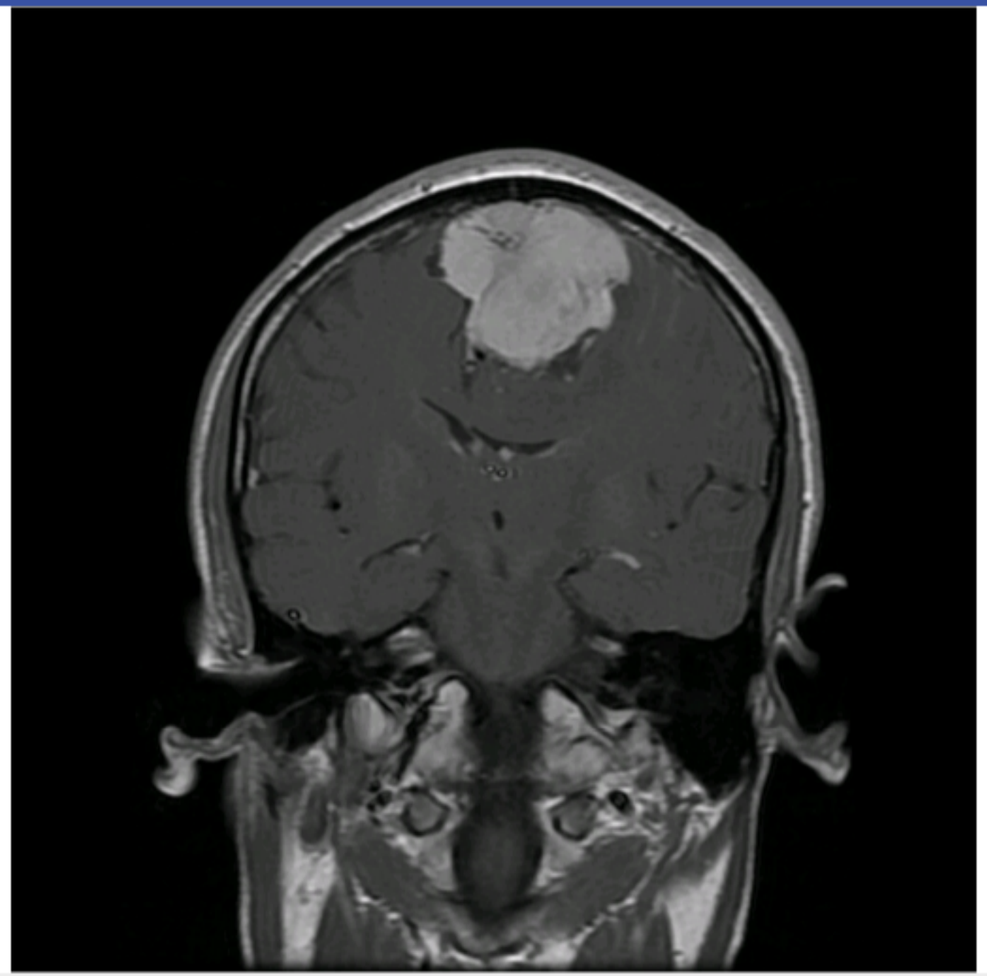

Zoom In | Zoom Out | Reset | Add To New Card | Existing Card

surround neuropil, forming Homer-Wright rosettes under light microscopy.

Exhibit Display

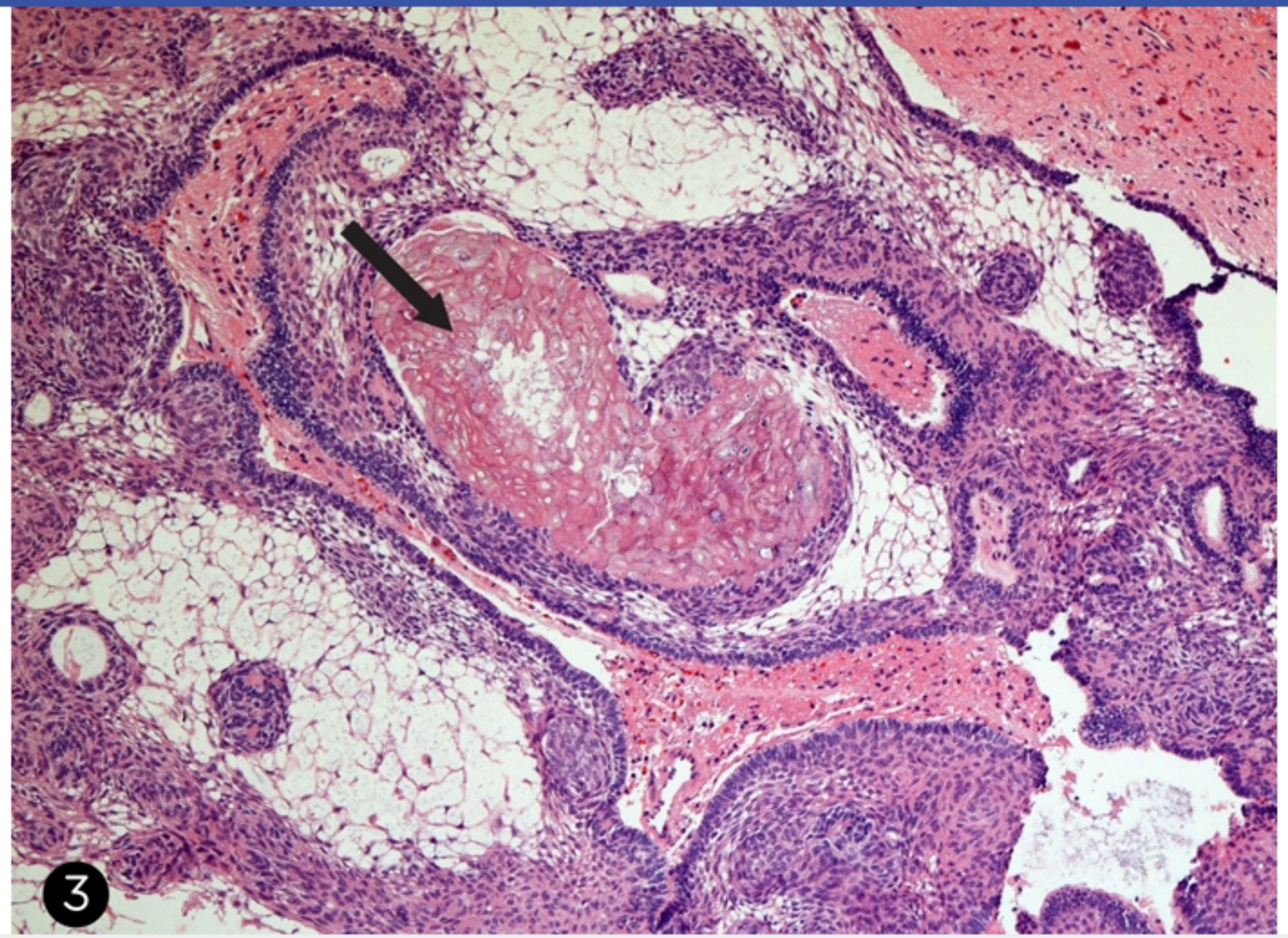

Zoom In | Zoom Out | Reset | Add To New Card | Existing Card

surround neuropil, forming Homer-Wright rosettes under light microscopy.

1
2
3
4
5
6
7
8
9
10
11
12
13
14
15
16
17
18
19

This patient's biopsy findings are consistent with **meningioma**, a slow-growing benign tumor derived from meningothelial cells of the arachnoid.

Note the whorled pattern (red arrow) of cellular growth that forms eosinophilic laminae (Antoni A pattern).

Exhibit Display

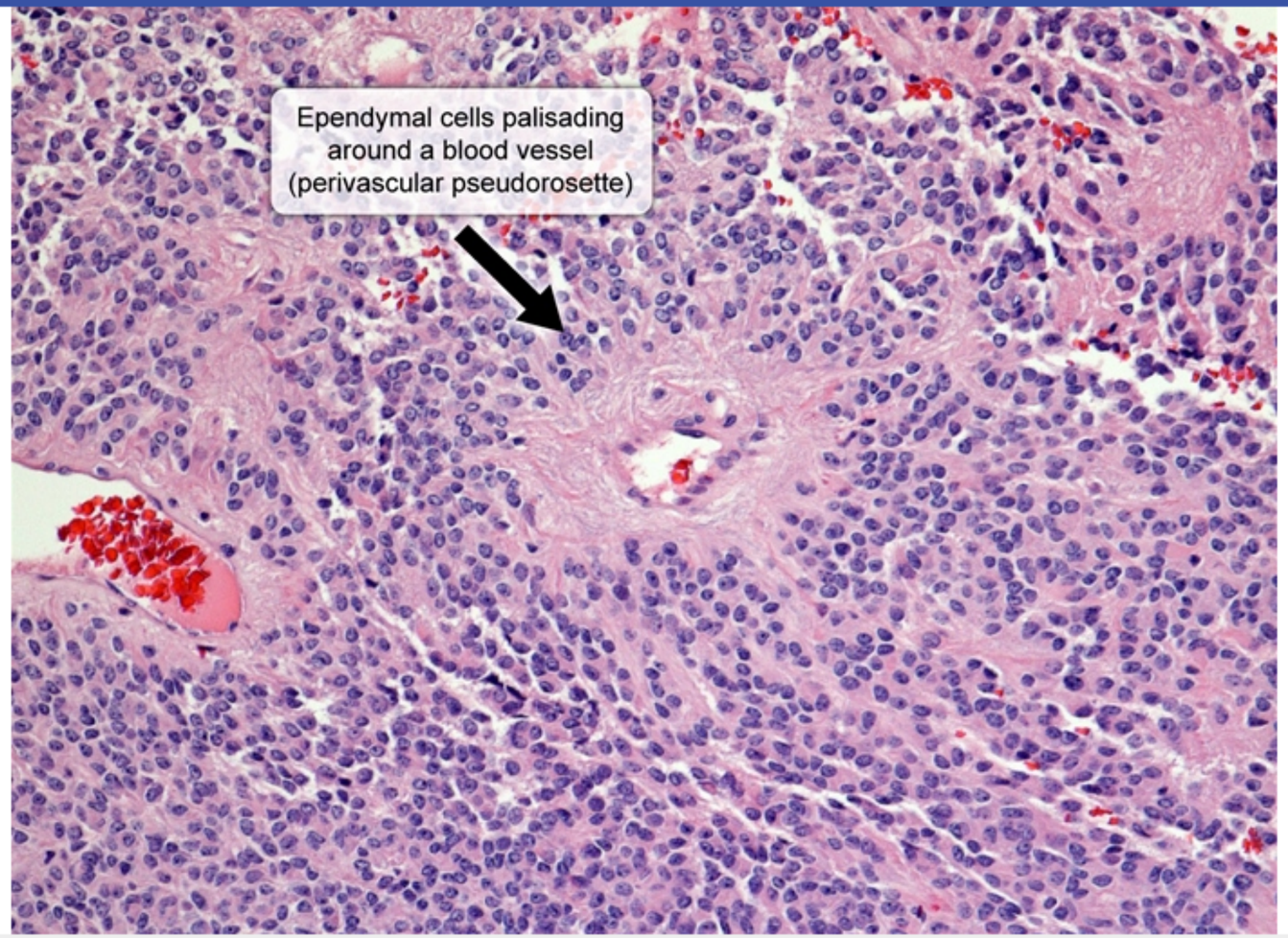

Zoom In | Zoom Out | Reset | Add To New Card | Existing Card

1
2
3
4
5
6
7
8
9
10
11
12
13
14
15
16
17
18
19

This patient's biopsy findings are consistent with **meningioma**, a slow-growing benign tumor derived from meningothelial cells of the arachnoid.

Note the whorled pattern (red arrow) of cellular growth that forms eosinophilic laminae (Antoni A pattern).

Exhibit Display

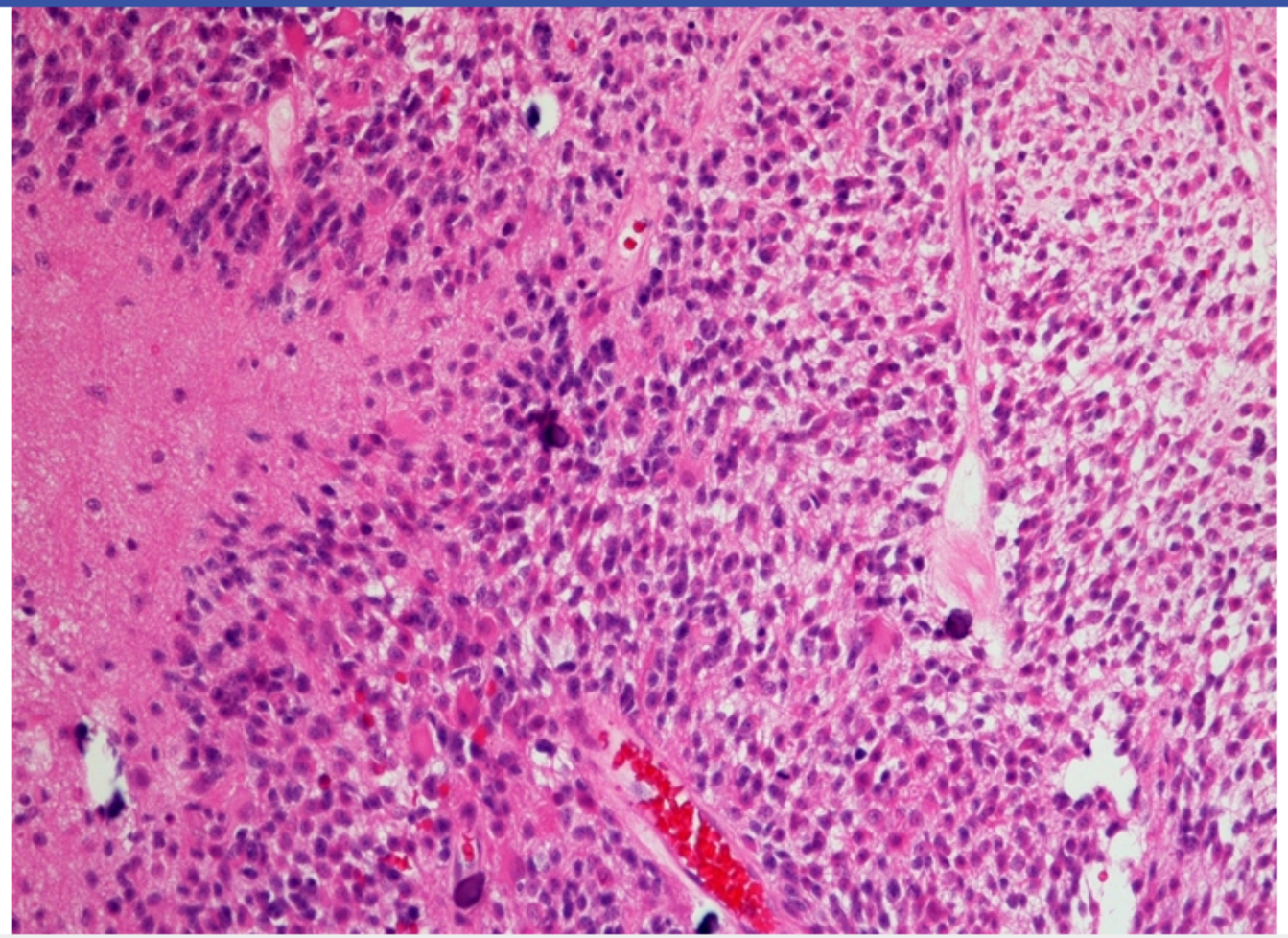

Zoom In | Zoom Out | Reset | Add To New Card | Existing Card

structures called psammoma bodies (black arrows). Other examples of tumors that form psammoma bodies include papillary thyroid carcinoma,

Exhibit Display

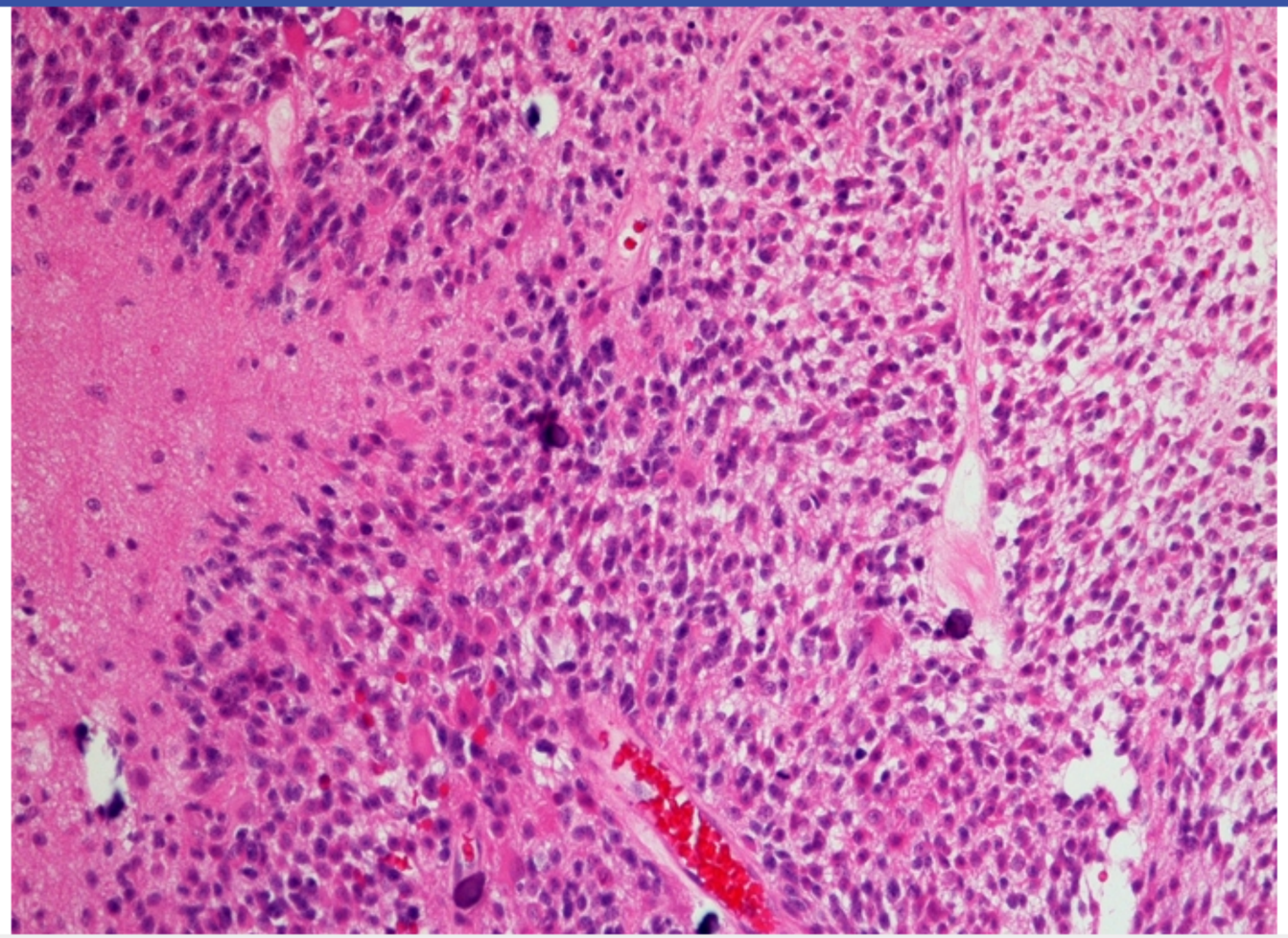

Zoom In Zoom Out Reset Add To New Card | Existing Card

Meningiomas are slow growing, well circumscribed, benign intracranial tumors typically found at the cerebral convexities in adults. Characteristic

structures called psammoma bodies (black arrows). Other examples of tumors that form psammoma bodies include papillary thyroid carcinoma,

Exhibit Display

Medulloblastoma Medulloblastoma

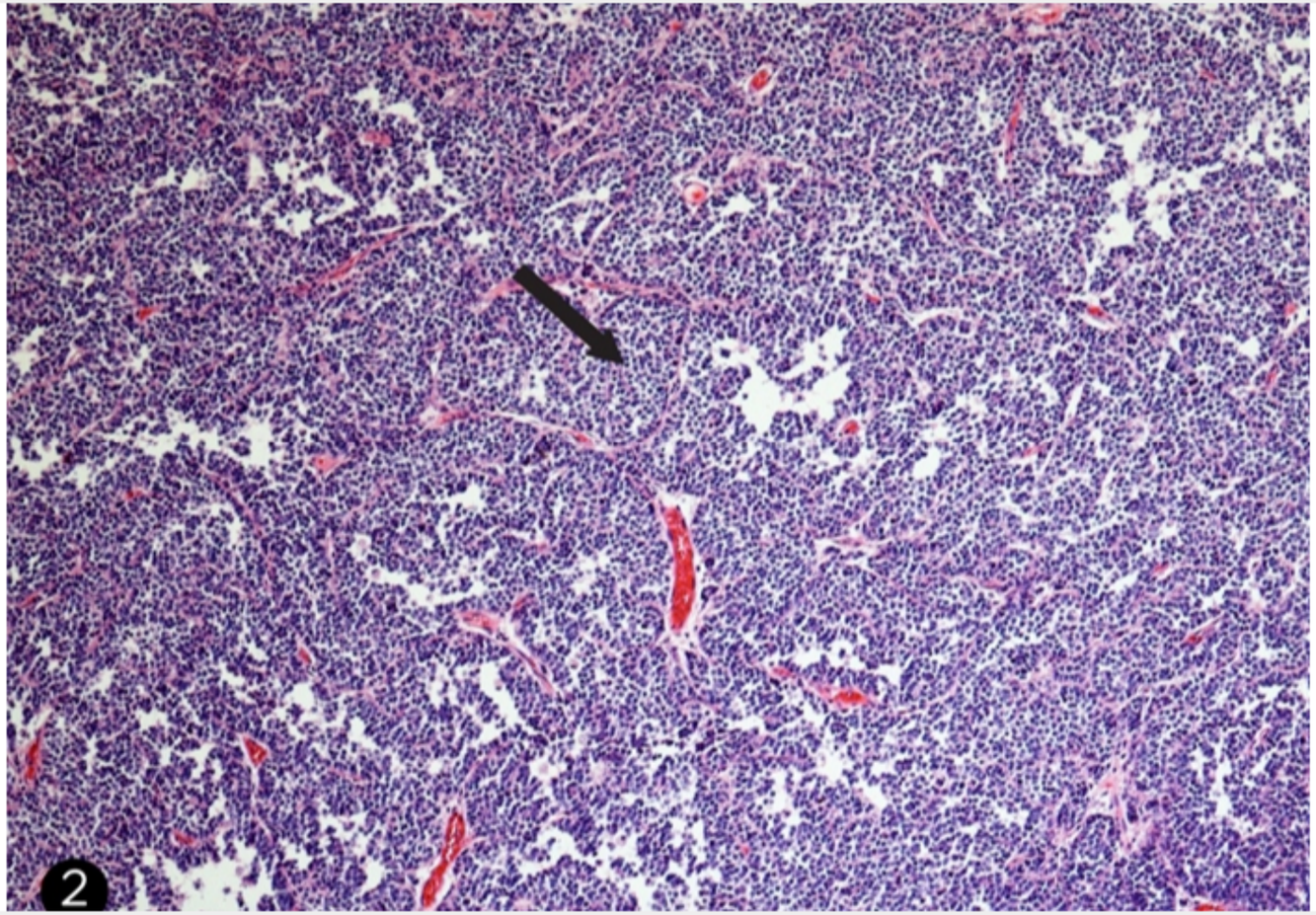

Zoom In Zoom Out Reset Add To New Card | Existing Card

Meningiomas are slow growing, well circumscribed, benign intracranial tumors typically found at the cerebral convexities in adults. Characteristic

structures called psammoma bodies (black arrows). Other examples of tumors that form psammoma bodies include papillary thyroid carcinoma,

Exhibit Display

Medulloblastoma Medulloblastoma

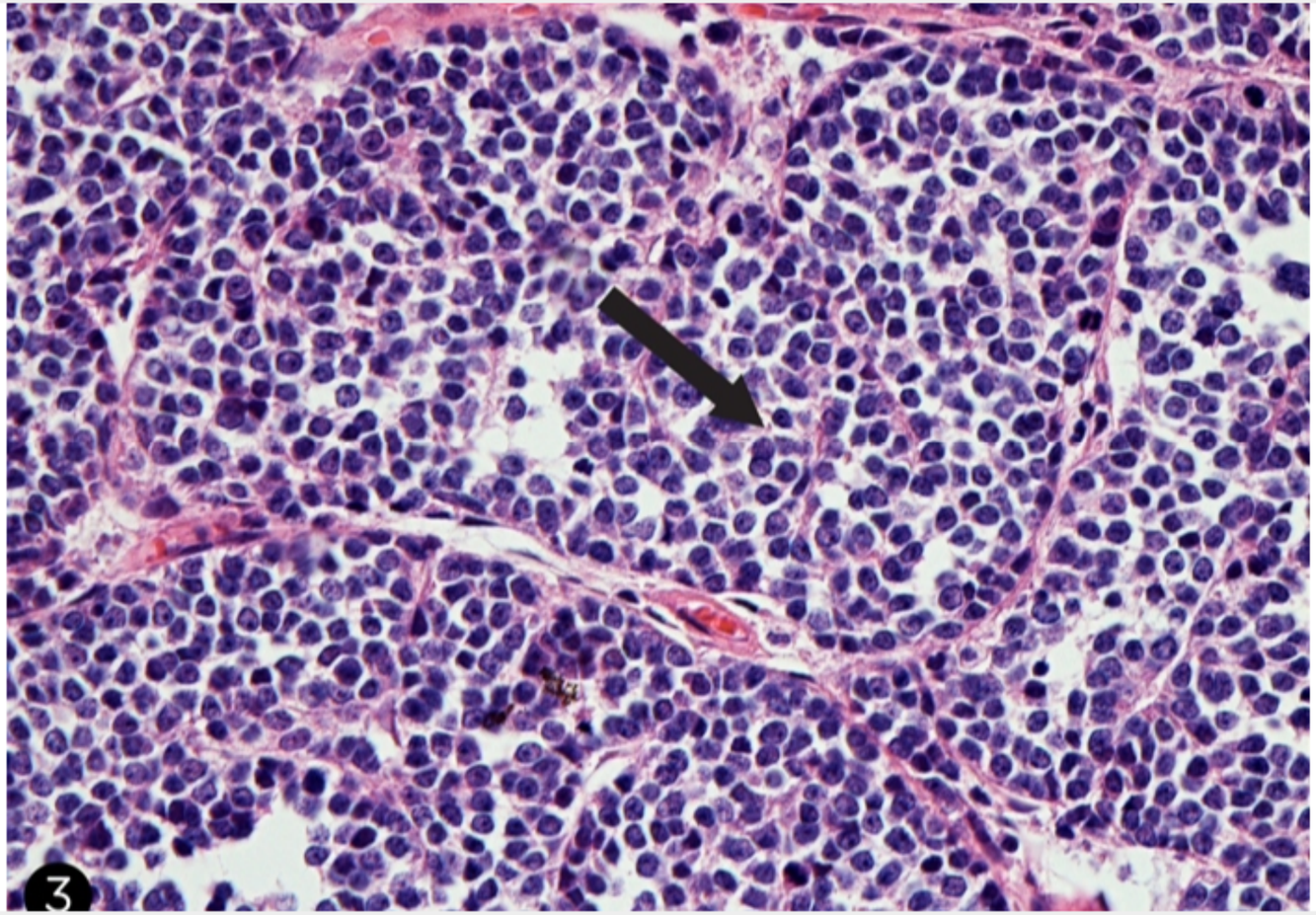

Zoom In Zoom Out Reset Add To New Card | Existing Card

Meningiomas are slow growing, well circumscribed, benign intracranial tumors typically found at the cerebral convexities in adults. Characteristic

structures called psammoma bodies (black arrows). Other examples of tumors that form psammoma bodies include papillary thyroid carcinoma,

Exhibit Display

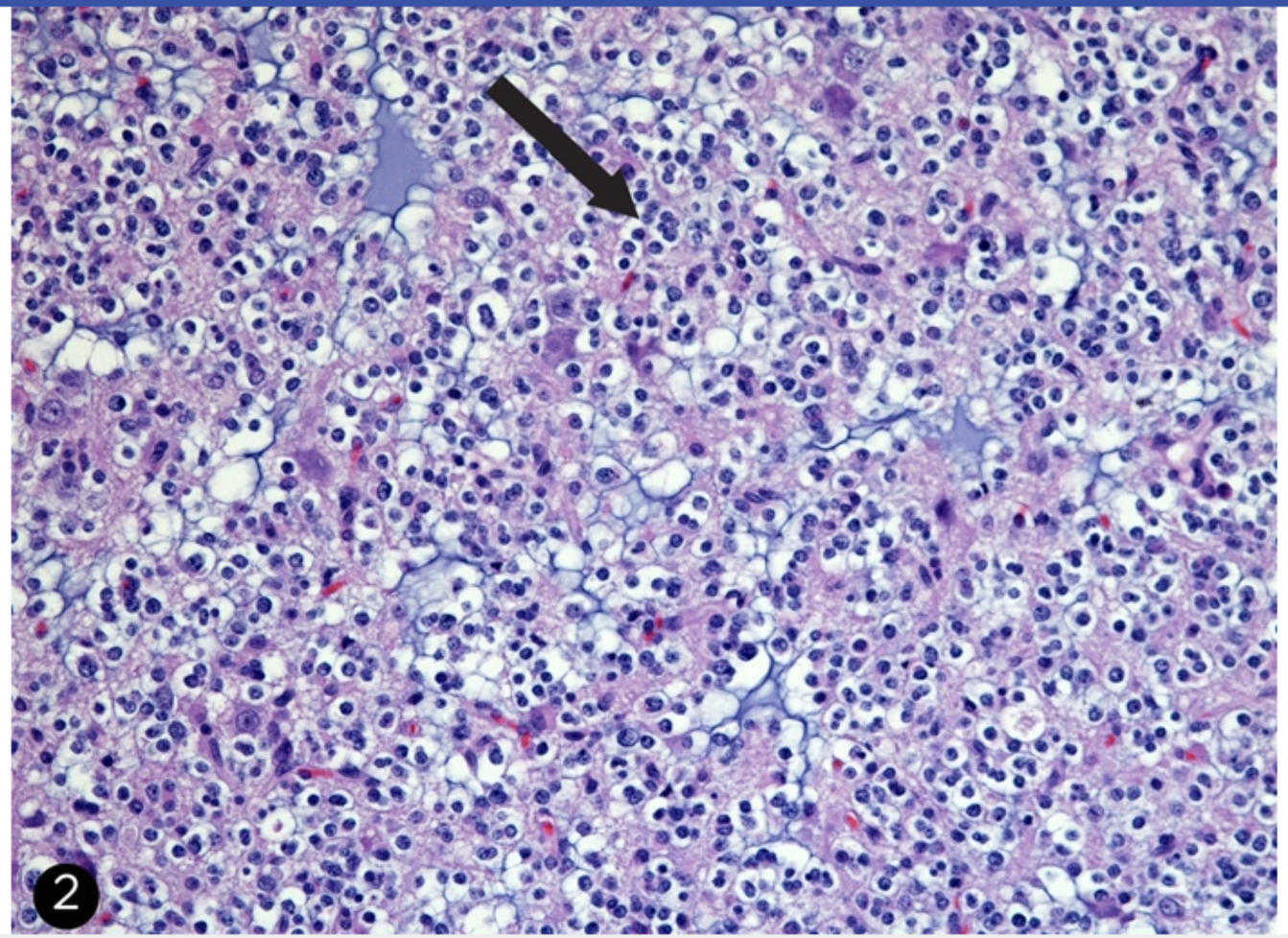

Zoom In Zoom Out Reset Add To New Card | Existing Card

Meningiomas are slow growing, well circumscribed, benign intracranial tumors typically found at the cerebral convexities in adults. Characteristic

structures called psammoma bodies (black arrows). Other examples of tumors that form psammoma bodies include papillary thyroid carcinoma,

Exhibit Display

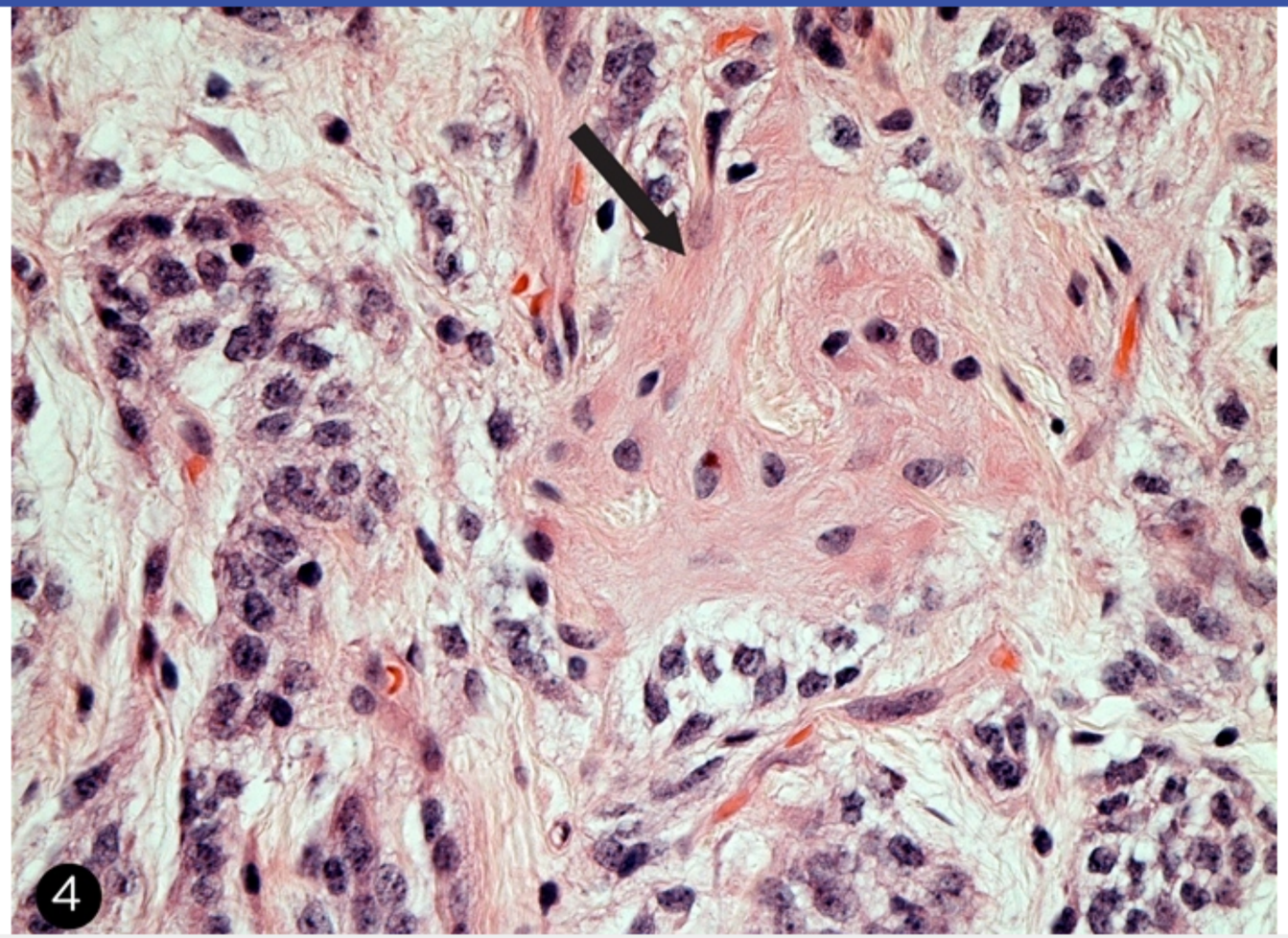

Zoom In Zoom Out Reset Add To New Card | Existing Card

Meningiomas are slow-growing, well-circumscribed, benign intracranial tumors typically found at the cerebral convexities in adults. Characteristic

structures called psammoma bodies (black arrows). Other examples of tumors that form psammoma bodies include papillary thyroid carcinoma,

Exhibit Display

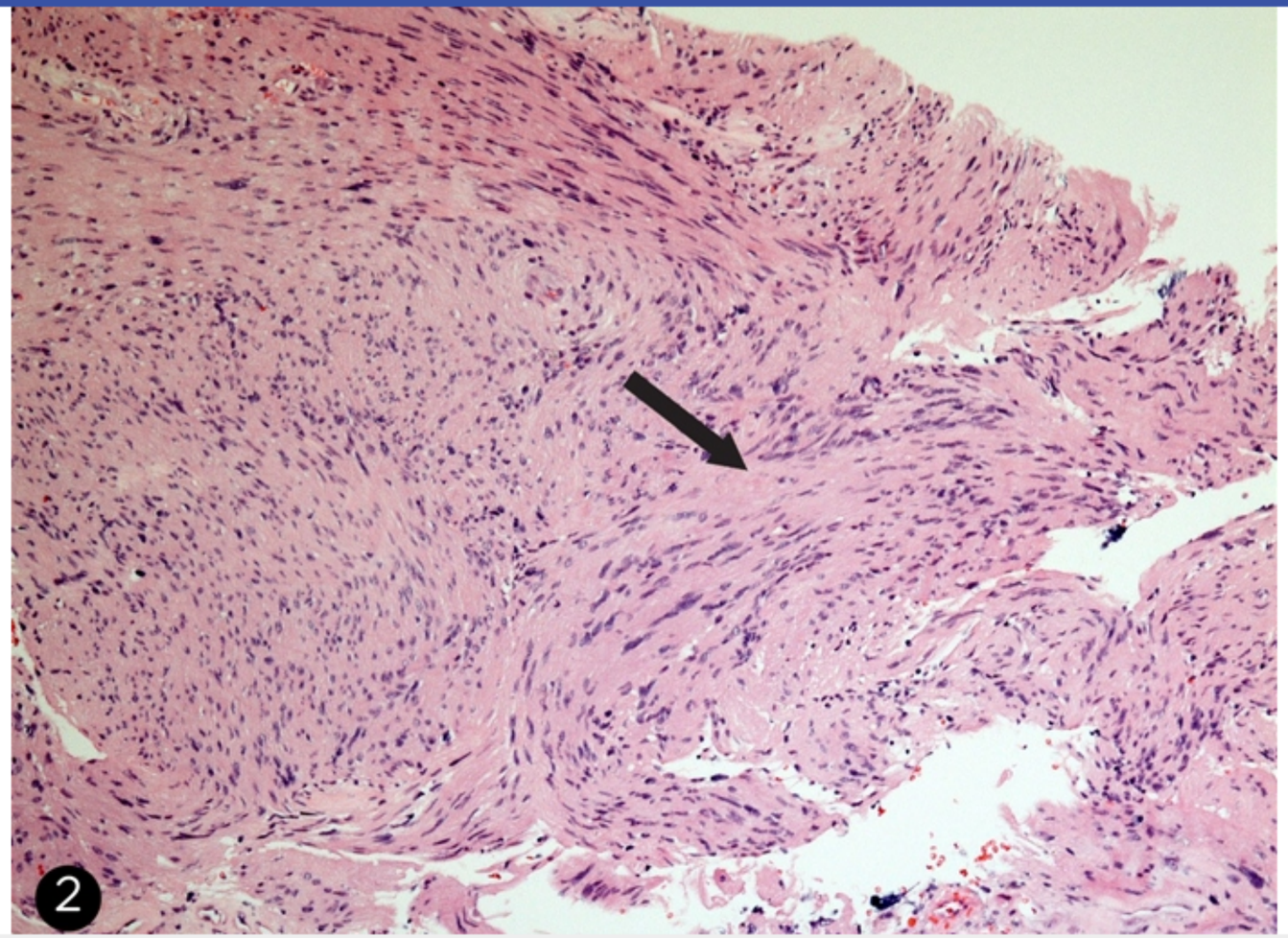

Zoom In
Zoom Out
Reset
Add To New Card | Existing Card

Meningiomas are slow growing, well circumscribed, benign intracranial tumors typically found at the cerebral convexities in adults. Characteristic

rosettes under light microscopy.

(Choice C) Glioblastomas are the most common primary malignant brain tumor in adults. They are often located in the cerebral hemispheres and may cross the corpus callosum ("butterfly glioma"). Light microscopy shows hypercellular areas of atypical astrocytes bordering regions of necrosis (pseudo-palisading).

(Choice D) Medulloblastomas are malignant cerebellar tumors that typically occur in children and are characterized by small blue cells that may surround neuropil, forming Homer-Wright rosettes under light microscopy.

(Choice F) Oligodendrogliomas typically involve the white matter of the cerebral hemispheres, and tumor cells have a "fried egg" appearance (round nuclei surrounded by a halo of clear cytoplasm) under light microscopy.

(Choice G) Pilocytic astrocytomas are usually benign tumors that involve the cerebellum in children and young adults. Tumor cells typically have eosinophilic granular bodies and elongated hairlike processes (Rosenthal fibers) under light microscopy.

(Choice H) Schwannomas are mostly benign tumors that commonly arise from the vestibular branch of cranial nerve VIII at the cerebellopontine angle. Light microscopy typically shows spindle cells with palisading nuclei arranged around Verocay bodies composed of eosinophilic cores (Antoni A pattern).

Educational objective:
Meningiomas are slow-growing, well-circumscribed, benign intracranial tumors typically found at the cerebral convexities in adults. Characteristic histopathologic features include a whorled pattern of cellular growth that forms nests, which may calcify into round, eosinophilic laminar structures called psammoma bodies.

References

- Review of meningioma histopathology.

Pathology	Nervous System	Brain tumors
Subject	System	Topic

Copyright © UWorld. All rights reserved.

A 68-year-old woman comes to the office due to tingling and numbness affecting her hands and legs. The patient's symptoms began 2 years ago with a "pins-and-needles" sensation in the soles of her feet, which has since progressed slowly upward to the mid-calf level. Lately, she has also had similar symptoms in her fingers. The patient has a 15-year history of type 2 diabetes mellitus complicated by diabetic retinopathy. Other medical conditions include hypertension and osteoarthritis. On physical examination, ankle reflexes are absent and sensation of joint position is decreased in the toes. Romberg sign is present. A lesion involving which of the following best explains this patient's findings?

A. Axons of unmyelinated C-type fibers

B. Distal axons of large sensory fibers

C. Lumbosacral spinal nerve roots

D. Myelin of peripheral motor neurons

E. Posterior and lateral spinal tracts

Submit

A 68-year-old woman comes to the office due to tingling and numbness affecting her hands and legs. The patient's symptoms began 2 years ago with a "pins-and-needles" sensation in the soles of her feet, which has since progressed slowly upward to the mid-calf level. Lately, she has also had similar symptoms in her fingers. The patient has a 15-year history of type 2 diabetes mellitus complicated by diabetic retinopathy. Other medical conditions include hypertension and osteoarthritis. On physical examination, ankle reflexes are absent and sensation of joint position is decreased in the toes. Romberg sign is present. A lesion involving which of the following best explains this patient's findings?

- A. Axons of unmyelinated C-type fibers (6%)
- ✓ B. Distal axons of large sensory fibers (49%)
- C. Lumbosacral spinal nerve roots (2%)
- D. Myelin of peripheral motor neurons (15%)
- E. Posterior and lateral spinal tracts (25%)

Omitted
Correct answer
B

49%
Answered correctly

02 secs
Time Spent

02/17/2020
Last Updated

Explanation

Diabetic neuropathy	
Risk factors	• Long duration of disease • Chronic hyperglycemia/poor glycemic control

Diabetic neuropathy	
Risk factors	• Long duration of disease • Chronic hyperglycemia/poor glycemic control
Pathogenesis	• Accumulation of glycosylation end products and sorbitol → altered metabolism and increased oxidative stress • Occlusion of vasa nervorum with nerve ischemia • Length-dependent axonopathy
Clinical manifestations	• **Peripheral polyneuropathy**: numbness, stocking-glove paresthesia, decreased proprioception • **Autonomic neuropathy**: gastroparesis, orthostasis, neurogenic bladder, erectile dysfunction • **Motor neuropathy**: distal limb weakness, hammer/claw toe deformities

This patient has numbness and paresthesias in a **stocking-glove distribution**, along with decreased proprioception (eg, decreased joint position sense) consistent with **diabetic polyneuropathy**. Diabetes mellitus is the most common cause of peripheral neuropathy in adults. The risk of neuropathy and other **microvascular complications** (eg, retinopathy, nephropathy) is increased in longstanding, poorly controlled diabetes; tight glycemic control can decrease the risk.

Neuronal injury occurs due to accumulation of advanced glycosylation end products, sorbitol, and other toxic substances that lead to deranged metabolism and increased oxidative stress. In addition, diabetic microangiopathy affecting the endoneurial vessels can promote nerve ischemia. This, in combination with the metabolic disturbances, leads to a **length-dependent axonopathy**, with clinical features occurring first in the longest nerves (eg, feet); symptoms vary depending on the type of nerve fibers involved:

- **Small-fiber** injury is characterized by predominance of **positive symptoms** (eg, pain, paresthesias, allodynia).
- **Large-fiber** involvement is characterized by predominance of **negative symptoms** (eg, numbness, loss of proprioception and vibration sense, sensory ataxia [eg, positive Romberg sign], diminished ankle reflexes).

Patients with diabetes can also develop autonomic neuropathy, manifesting as gastrointestinal disturbances (eg, gastroparesis), orthostatic symptoms, bladder dysfunction, and erectile dysfunction. Degeneration of motor axons may also occur, leading to unbalanced strength in the

Neuronal injury occurs due to accumulation of advanced glycosylation end products, sorbitol, and other toxic substances that lead to deranged metabolism and increased oxidative stress. In addition, diabetic microangiopathy affecting the endoneurial vessels can promote nerve ischemia. This, in combination with the metabolic disturbances, leads to a **length-dependent axonopathy**, with clinical features occurring first in the longest nerves (eg, feet); symptoms vary depending on the type of nerve fibers involved:

- **Small-fiber** injury is characterized by predominance of **positive symptoms** (eg, pain, paresthesias, allodynia).
- **Large-fiber** involvement is characterized by predominance of **negative symptoms** (eg, numbness, loss of proprioception and vibration sense, sensory ataxia [eg, positive Romberg sign], diminished ankle reflexes).

Patients with diabetes can also develop autonomic neuropathy, manifesting as gastrointestinal disturbances (eg, gastroparesis), orthostatic symptoms, bladder dysfunction, and erectile dysfunction. Degeneration of motor axons may also occur, leading to unbalanced strength in the extremities and hammer or claw toe deformities.

(Choice A) C-fibers are small, unmyelinated fibers that carry pain and temperature sensation. Diabetes can damage these fibers, leading to a reduction in pain/temperature sensation as well as burning pain. Numbness, tingling paresthesias, diminished reflexes, and sensory ataxia are more consistent with large-fiber neuropathy.

(Choice C) Nerve root dysfunction (ie, radiculopathy) is most commonly due to compression from disc herniation or degenerative changes in the vertebral column. The associated pain/numbness is in a dermatomal (rather than stocking-glove) distribution and is often associated with muscular weakness and atrophy.

(Choice D) Guillain-Barré syndrome is an immune-mediated polyneuropathy caused by demyelination of peripheral nerve fibers. It can cause paresthesias and neuropathic pain but typically presents with rapidly progressive ascending weakness. Most patients have a preceding respiratory or gastrointestinal infection (eg, *Campylobacter*).

(Choice E) Subacute combined degeneration of the spinal cord results from chronic vitamin B_{12} deficiency. Manifestations in the posterior columns can include loss of proprioception, paresthesia, and sensory ataxia, but concurrent lateral corticospinal tract signs (eg, spastic paresis) and other signs of B_{12} deficiency (eg, atrophic glossitis, macrocytic anemia) are typically present.

Educational objective:
Diabetes mellitus is the most common cause of peripheral polyneuropathy in adults. Common findings include numbness and paresthesias in a

Neuronal injury occurs due to accumulation of advanced glycosylation end products, sorbitol, and other toxic substances that lead to deranged

Exhibit Display

Hammer & claw toe deformities

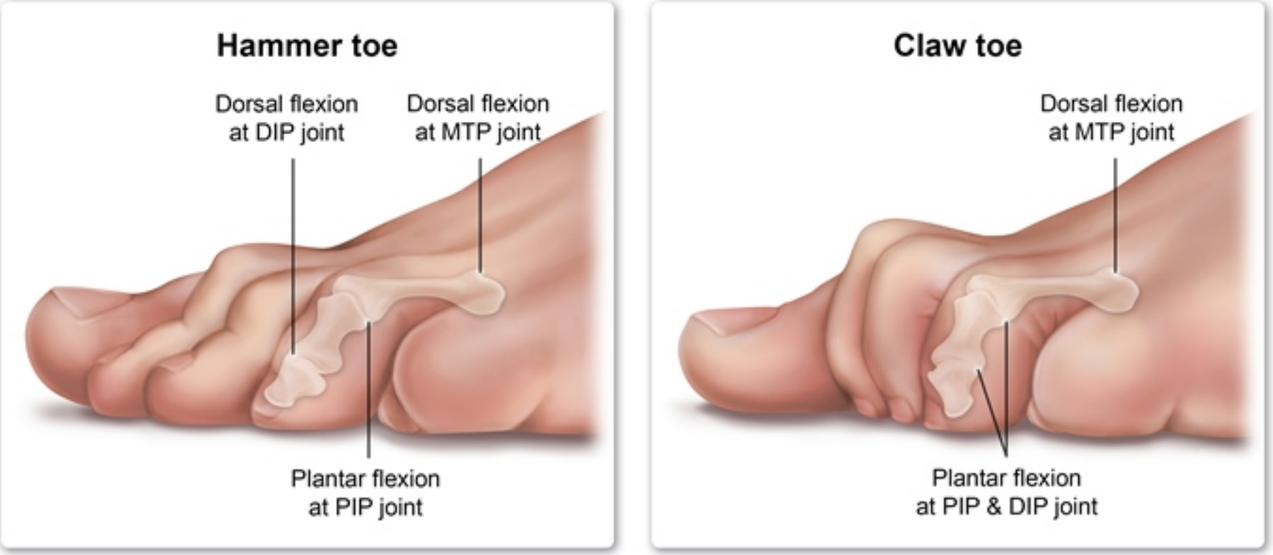

DIP = distal interphalangeal; **MTP** = metatarsophalangeal; **PIP** = proximal interphalangeal.

©UWorld

Zoom In | Zoom Out | Reset | Add To New Card | Existing Card

Diabetes mellitus is the most common cause of peripheral polyneuropathy in adults. Common findings include numbness and paresthesias in a

sense, sensory ataxia [eg, positive Romberg sign], diminished ankle reflexes).

Patients with diabetes can also develop autonomic neuropathy, manifesting as gastrointestinal disturbances (eg, gastroparesis), orthostatic symptoms, bladder dysfunction, and erectile dysfunction. Degeneration of motor axons may also occur, leading to unbalanced strength in the extremities and hammer or claw toe deformities.

(Choice A) C-fibers are small, unmyelinated fibers that carry pain and temperature sensation. Diabetes can damage these fibers, leading to a reduction in pain/temperature sensation as well as burning pain. Numbness, tingling paresthesias, diminished reflexes, and sensory ataxia are more consistent with large-fiber neuropathy.

(Choice C) Nerve root dysfunction (ie, radiculopathy) is most commonly due to compression from disc herniation or degenerative changes in the vertebral column. The associated pain/numbness is in a dermatomal (rather than stocking-glove) distribution and is often associated with muscular weakness and atrophy.

(Choice D) Guillain-Barré syndrome is an immune-mediated polyneuropathy caused by demyelination of peripheral nerve fibers. It can cause paresthesias and neuropathic pain but typically presents with rapidly progressive ascending weakness. Most patients have a preceding respiratory or gastrointestinal infection (eg, *Campylobacter*).

(Choice E) Subacute combined degeneration of the spinal cord results from chronic vitamin B_{12} deficiency. Manifestations in the posterior columns can include loss of proprioception, paresthesia, and sensory ataxia, but concurrent lateral corticospinal tract signs (eg, spastic paresis) and other signs of B_{12} deficiency (eg, atrophic glossitis, macrocytic anemia) are typically present.

Educational objective:
Diabetes mellitus is the most common cause of peripheral polyneuropathy in adults. Common findings include numbness and paresthesias in a stocking-glove distribution and decreased proprioception due to degeneration of large-fiber sensory axons.

Pathology	Nervous System	Diabetic neuropathy
Subject	System	Topic

Copyright © UWorld. All rights reserved.

A gross brain section of a 54-year-old male who suffered from severe tuberculous meningitis is shown below.

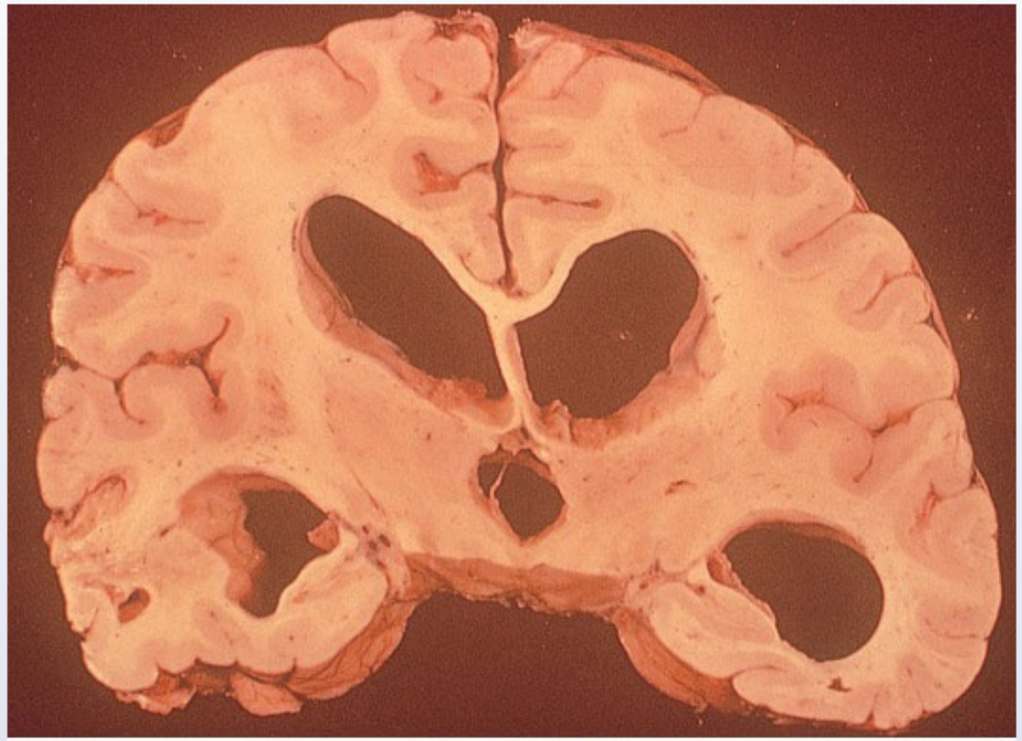

Displayed with permission from Springer Healthcare Ltd. © Copyright 2002 by Current Medicine

This patient's condition is most likely related to impaired function of which of the following?

- A. Emissary veins
- B. Arachnoid trabeculae
- C. Arachnoid granulations

1
2
3
4
5
6
7
8
9
10
11
12
13
14
15
16
17
18
19

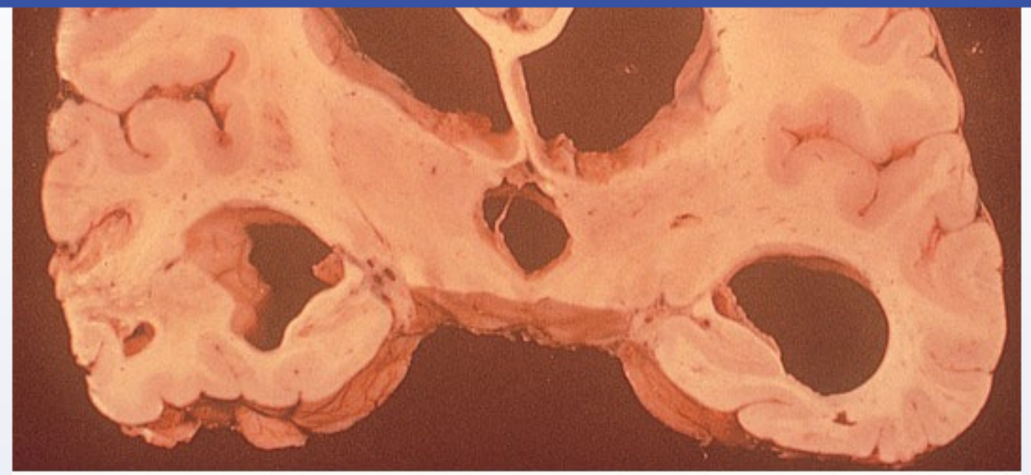

Displayed with permission from Springer Healthcare Ltd. © Copyright 2002 by Current Medicine

This patient's condition is most likely related to impaired function of which of the following?

- A. Emissary veins
- B. Arachnoid trabeculae
- C. Arachnoid granulations
- D. Choroid plexus
- E. Dural septae
- F. Communicating arteries

Submit

1
2
3
4
5
6
7
8
9
10
11
12
13
14
15
16
17
18
19

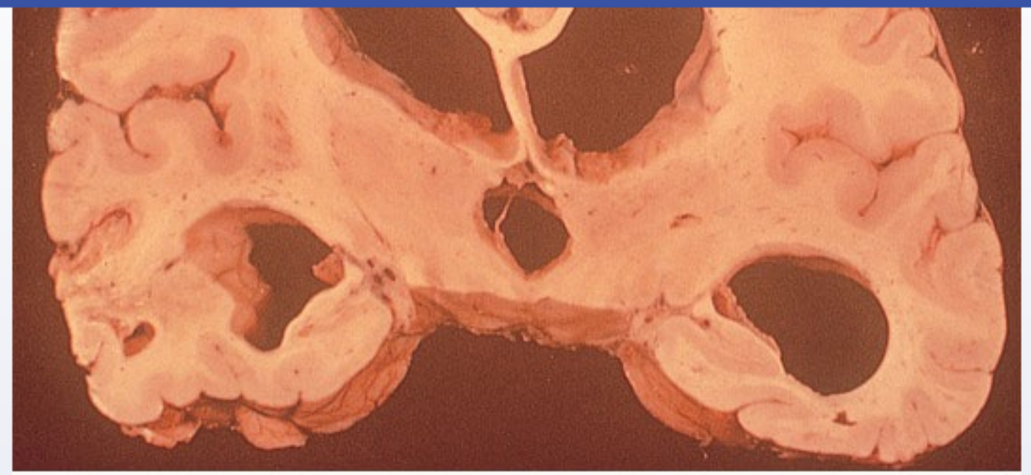

Displayed with permission from Springer Healthcare Ltd. © Copyright 2002 by Current Medicine

This patient's condition is most likely related to impaired function of which of the following?

- A. Emissary veins (2%)
- B. Arachnoid trabeculae (6%)
- ✓ C. Arachnoid granulations (67%)
- D. Choroid plexus (17%)
- E. Dural septae (2%)
- F. Communicating arteries (3%)

Omitted
Correct answer

67%
Answered correctly

04 secs
Time Spent

06/24/2020
Last Updated

Explanation

Cerebrospinal fluid (CSF) is secreted by the choroid plexus of the lateral and fourth ventricles. The path of CSF flow is as follows: lateral ventricles → interventricular foramen of Monro → the third ventricle → cerebral aqueduct → the fourth ventricle → the foramina of Luschka and Magendie → subarachnoid space. In the subarachnoid space, CSF is absorbed by arachnoid granulations and then enters the venous sinuses. The dynamic balance between production and absorption of CSF allows stable intracranial volume (120-150 ml) and pressure (50-180 mm H_2O).

If the normal flow of CSF from the ventriculi to the subarachnoid space is disrupted, **non-communicating hydrocephalus** occurs. Ventriculi above the obstruction are enlarged, while those below the obstruction are normal. Congenital anomalies, such as aqueductal stenosis, Arnold-Chiari or Dandy-Walker malformations, cause non-communicating hydrocephalus. In all cases, the obstacle to CSF flow exists within the ventriculi.

In **communicating hydrocephalus**, there is no obstruction to CSF flow from the ventriculi to the subarachnoid space. Communicating hydrocephalus usually occurs secondary to dysfunction or obliteration of subarachnoid villi. This dysfunction is usually a sequelae of meningeal infections (including tuberculosis meningitis, as in this patient) or subarachnoid/intraventricular hemorrhage. In communicating hydrocephalus, all ventriculi are symmetrically enlarged, as in the image above.

(Choice A) The emissary veins pass through apertures between the intracranial sinuses and veins outside the cranial vault. They do not participate in absorption of CSF.

(Choice B) Arachnoid trabeculae pass from the arachnoid through the subarachnoid space to the pia mater. They are not involved in the metabolism of CSF.

(Choice D) The choroid plexus is the site of CSF secretion; in communicating hydrocephalus, CSF absorption, not secretion, is impaired. If present, a choroid plexus papilloma might cause a symmetric ventricular enlargement that appears virtually identical to communicating hydrocephalus. Communicating hydrocephalus is far more common than choroid plexus papilloma, however, making Choice D a plausible answer, but not the most likely one.

(Choices E and F) Neither dural septae nor communicating arteries are implicated in the pathogenesis of communicating hydrocephalus.

Educational Objective:

Chiari or Dandy-Walker malformations, cause non-communicating hydrocephalus. In all cases, the obstacle to CSF flow exists within the ventriculi.

In **communicating hydrocephalus**, there is no obstruction to CSF flow from the ventriculi to the subarachnoid space. Communicating hydrocephalus usually occurs secondary to dysfunction or obliteration of subarachnoid villi. This dysfunction is usually a sequelae of meningeal infections (including tuberculosis meningitis, as in this patient) or subarachnoid/intraventricular hemorrhage. In communicating hydrocephalus, all ventriculi are symmetrically enlarged, as in the image above.

(Choice A) The emissary veins pass through apertures between the intracranial sinuses and veins outside the cranial vault. They do not participate in absorption of CSF.

(Choice B) Arachnoid trabeculae pass from the arachnoid through the subarachnoid space to the pia mater. They are not involved in the metabolism of CSF.

(Choice D) The choroid plexus is the site of CSF secretion; in communicating hydrocephalus, CSF absorption, not secretion, is impaired. If present, a choroid plexus papilloma might cause a symmetric ventricular enlargement that appears virtually identical to communicating hydrocephalus. Communicating hydrocephalus is far more common than choroid plexus papilloma, however, making Choice D a plausible answer, but not the most likely one.

(Choices E and F) Neither dural septae nor communicating arteries are implicated in the pathogenesis of communicating hydrocephalus.

Educational Objective:
Symmetrical enlargement of the ventriculi is characteristic of communicating hydrocephalus. Communicating hydrocephalus usually occurs secondary to dysfunction or obliteration of subarachnoid villi. This dysfunction is usually a sequelae of meningeal infection (including tuberculosis meningitis) or subarachnoid/intraventricular hemorrhage.

Pathology	Nervous System	Hydrocephalus
Subject	System	Topic

Copyright © UWorld. All rights reserved.

A 21-year-old man comes to the office with impaired balance, tremor, and difficulty speaking. His symptoms have developed slowly over the last several months. The patient is found to have elevated serum transaminases. Viral hepatitis serologies are negative. He does not use tobacco, alcohol, or illicit drugs. He has a sibling who was diagnosed at a young age with a progressive neurologic disease. Which of the following diagnostic studies would be the most helpful for confirming the diagnosis in this patient?

A. Anti-smooth muscle antibodies

B. Genetic testing for triplet repeat expansions

C. MRI of the brain

D. Serum alpha-1 antitrypsin level

E. Serum ferritin and transferrin saturation

F. Slit lamp examination

Submit

A 21-year-old man comes to the office with impaired balance, tremor, and difficulty speaking. His symptoms have developed slowly over the last several months. The patient is found to have elevated serum transaminases. Viral hepatitis serologies are negative. He does not use tobacco, alcohol, or illicit drugs. He has a sibling who was diagnosed at a young age with a progressive neurologic disease. Which of the following diagnostic studies would be the most helpful for confirming the diagnosis in this patient?

A. Anti-smooth muscle antibodies (4%)

B. Genetic testing for triplet repeat expansions (28%)

C. MRI of the brain (13%)

D. Serum alpha-1 antitrypsin level (3%)

E. Serum ferritin and transferrin saturation (10%)

✓ F. Slit lamp examination (40%)

Omitted
Correct answer
F

40%
Answered correctly

01 sec
Time Spent

01/13/2020
Last Updated

Explanation

Wilson disease	
Pathogenesis	• Autosomal recessive mutation of *ATP7B* → hepatic copper accumulation → leak from damaged hepatocytes → deposits

Wilson disease	
Pathogenesis	• Autosomal recessive mutation of *ATP7B* → hepatic copper accumulation → leak from damaged hepatocytes → deposits in tissues (eg, basal ganglia, cornea)
Clinical findings	• Hepatic (acute liver failure, chronic hepatitis, cirrhosis) • Neurologic (parkinsonism, gait disturbance, dysarthria) • Psychiatric (depression, personality changes, psychosis)
Diagnosis	• ↓ Ceruloplasmin & ↑ urinary copper excretion • Kayser-Fleischer rings on slit-lamp examination • ↑ Copper content on liver biopsy
Treatment	• Chelators (eg, D-penicillamine, trientine) • Zinc (interferes with copper absorption)

Wilson disease is a rare, autosomal recessive disorder most often identified in individuals age 5-40. A mutation of gene *ATP7B* hinders intracellular hepatocyte copper transport, causing reduced formation/secretion of ceruloplasmin (the major extracellular copper transport protein) and **decreased secretion of copper** into the biliary system. Copper is a pro-oxidant and causes **hepatocellular injury** by producing free radicals. Eventually, copper leaks from injured hepatocytes into the blood to be deposited in various tissues (eg, basal ganglia, cornea).

Neurologic involvement can result in **movement abnormalities** and **psychiatric symptoms**. Almost all patients with neuropsychiatric disease have Kayser-Fleischer rings (green/brown copper deposits in the Descemet membrane of the cornea), which can be detected on slit lamp examination if not seen on visual inspection. The diagnosis can be confirmed by the presence of **low serum ceruloplasmin**, increased urinary copper excretion, and elevated hepatic copper content on liver biopsy.

(Choice A) Anti-smooth muscle antibodies are associated with autoimmune hepatitis. Although serum transaminases can be elevated, neurologic symptoms are not characteristic.

Wilson disease is a rare, autosomal recessive disorder most often identified in individuals age 5-40. A mutation of gene *ATP7B* hinders intracellular hepatocyte copper transport, causing reduced formation/secretion of ceruloplasmin (the major extracellular copper transport protein) and **decreased secretion of copper** into the biliary system. Copper is a pro-oxidant and causes **hepatocellular injury** by producing free radicals. Eventually, copper leaks from injured hepatocytes into the blood to be deposited in various tissues (eg, basal ganglia, cornea).

Neurologic involvement can result in **movement abnormalities** and **psychiatric symptoms**. Almost all patients with neuropsychiatric disease have Kayser-Fleischer rings (green/brown copper deposits in the Descemet membrane of the cornea), which can be detected on slit lamp examination if not seen on visual inspection. The diagnosis can be confirmed by the presence of **low serum ceruloplasmin**, increased urinary copper excretion, and elevated hepatic copper content on liver biopsy.

(Choice A) Anti-smooth muscle antibodies are associated with autoimmune hepatitis. Although serum transaminases can be elevated, neurologic symptoms are not characteristic.

(Choice B) Genetic testing for triplet repeat expansions may be considered in patients with suspected Friedreich ataxia, an autosomal recessive disorder that typically presents during adolescence with neurologic dysfunction (eg, limb/gait ataxia, dysarthria) and hypertrophic cardiomyopathy.

(Choice C) Although atrophy/cavitation of the basal ganglia may be identified on brain MRI in patients with advanced Wilson disease, these findings are not specific and therefore are not used to confirm the diagnosis. Neuroimaging can be useful in excluding other causes of movement disorder (eg, tumor, infarction, demyelinating disease).

(Choice D) Alpha-1 antitrypsin deficiency is an autosomal codominant disorder that usually presents with early onset (age ≤45), panacinar emphysema, and liver disease.

(Choice E) Elevated serum ferritin and transferrin saturation is characteristic of hemochromatosis, an autosomal recessive disorder associated with increased intestinal iron absorption. Patients typically present with liver disease, skin pigmentation, diabetes mellitus, and cardiac enlargement due to excessive iron deposition into tissues.

Educational objective:
Wilson disease is an autosomal recessive condition characterized by excessive copper deposition into tissues (eg, liver, basal ganglia, cornea). It typically presents in young adults with liver disease, neuropsychiatric symptoms (eg, gait disturbance, dysarthria, depression, personality changes), and Kayser-Fleischer rings on slit lamp examination.

Wilson disease is a rare, autosomal recessive disorder most often identified in individuals age 5-40. A mutation of gene *ATP7B* hinders

Exhibit Display

Zoom In | Zoom Out | Reset | Add To New Card | Existing Card

changes), and Kayser-Fleischer rings on slit lamp examination.

copper excretion, and elevated hepatic copper content on liver biopsy.

(Choice A) Anti-smooth muscle antibodies are associated with autoimmune hepatitis. Although serum transaminases can be elevated, neurologic symptoms are not characteristic.

(Choice B) Genetic testing for triplet repeat expansions may be considered in patients with suspected Friedreich ataxia, an autosomal recessive disorder that typically presents during adolescence with neurologic dysfunction (eg, limb/gait ataxia, dysarthria) and hypertrophic cardiomyopathy.

(Choice C) Although atrophy/cavitation of the basal ganglia may be identified on brain MRI in patients with advanced Wilson disease, these findings are not specific and therefore are not used to confirm the diagnosis. Neuroimaging can be useful in excluding other causes of movement disorder (eg, tumor, infarction, demyelinating disease).

(Choice D) Alpha-1 antitrypsin deficiency is an autosomal codominant disorder that usually presents with early onset (age ≤45), panacinar emphysema, and liver disease.

(Choice E) Elevated serum ferritin and transferrin saturation is characteristic of hemochromatosis, an autosomal recessive disorder associated with increased intestinal iron absorption. Patients typically present with liver disease, skin pigmentation, diabetes mellitus, and cardiac enlargement due to excessive iron deposition into tissues.

Educational objective:
Wilson disease is an autosomal recessive condition characterized by excessive copper deposition into tissues (eg, liver, basal ganglia, cornea). It typically presents in young adults with liver disease, neuropsychiatric symptoms (eg, gait disturbance, dysarthria, depression, personality changes), and Kayser-Fleischer rings on slit lamp examination.

References

- Wilson disease.

Pathology	Nervous System	Wilson disease
Subject	System	Topic

Copyright © UWorld. All rights reserved.

A 63-year-old man collapses at home after experiencing severe retrosternal chest pain. The emergency medical team finds him with no pulse, and cardiac monitoring shows ventricular fibrillation. Cardiopulmonary resuscitation is performed, and the patient regains spontaneous circulation after several minutes. On arrival at the hospital, he has stable vital signs but does not follow commands or respond to strong stimuli. Which of the following areas is most likely to be affected first by ischemic damage in this patient?

A. Caudate nucleus

B. Hippocampus

C. Hypothalamus

D. Substantia nigra

E. Thalamic nuclei

Submit

A 63-year-old man collapses at home after experiencing severe retrosternal chest pain. The emergency medical team finds him with no pulse, and cardiac monitoring shows ventricular fibrillation. Cardiopulmonary resuscitation is performed, and the patient regains spontaneous circulation after several minutes. On arrival at the hospital, he has stable vital signs but does not follow commands or respond to strong stimuli. Which of the following areas is most likely to be affected first by ischemic damage in this patient?

- A. Caudate nucleus (5%)
- ✓ B. Hippocampus (64%)
- C. Hypothalamus (5%)
- D. Substantia nigra (1%)
- E. Thalamic nuclei (23%)

Omitted
Correct answer
B

64%
Answered correctly

02 secs
Time Spent

03/24/2020
Last Updated

Explanation

This patient's cardiac arrest, secondary to ventricular fibrillation, caused rapid cessation of cerebral blood flow and **global cerebral ischemia**. Although cardiac function and circulation were restored after medical intervention, the patient's brain was subjected to ischemia for an unknown length of time, resulting in neurological impairment.

Global ischemia lasting longer than 3-5 minutes can cause irreversible damage to neurons. The cells that are typically **affected first** by hypoxia are the CA1 pyramidal neurons of the **hippocampus**, which can be damaged by ischemia in as little as 3 minutes. The cerebellar Purkinje cells

This patient's cardiac arrest, secondary to ventricular fibrillation, caused rapid cessation of cerebral blood flow and **global cerebral ischemia**. Although cardiac function and circulation were restored after medical intervention, the patient's brain was subjected to ischemia for an unknown length of time, resulting in neurological impairment.

Global ischemia lasting longer than 3-5 minutes can cause irreversible damage to neurons. The cells that are typically **affected first** by hypoxia are the CA1 pyramidal neurons of the **hippocampus**, which can be damaged by ischemia in as little as 3 minutes. The cerebellar Purkinje cells and neocortex pyramidal neurons are also highly susceptible to damage if ischemia lasts for 5-10 minutes. These neurons are likely vulnerable to ischemia because of their **high metabolic demand** and unique neurochemical characteristics (eg, inability to repolarize after anoxic depolarization).

The hippocampus is located in the medial temporal lobe and plays an essential role in memory, spatial processing, and response inhibition. Selective damage to the hippocampus is common with transient ischemia and can result in an inability to make new memories (anterograde amnesia) and disorientation to place or time.

(Choices A, C, D, and E) Although the caudate nucleus, hypothalamus, substantia nigra, and thalamic nuclei are also vulnerable to ischemia if cerebral hypoxia is sustained, they are not as susceptible to damage as the hippocampal CA1 pyramidal neurons.

Educational objective:
Global cerebral ischemia is typically precipitated by systemic hypotension (eg, cardiac arrest). The cells most susceptible to ischemia are the CA1 pyramidal neurons of the hippocampus. Other areas of the brain that are damaged early in the course of global cerebral ischemia include the cerebellar Purkinje cells and the pyramidal neurons of the neocortex.

References

- Mechanisms of injury in hypoxic-ischemic encephalopathy: implications to therapy.
- Mechanisms of brain injury after global cerebral ischemia.

Pathology	Nervous System	Ischemic stroke
Subject	System	Topic

A 24-year-old man comes to the physician with complaints of tinnitus, vertigo, and hearing loss. A contrast-enhanced, T1-weighted image of his brain is shown below.

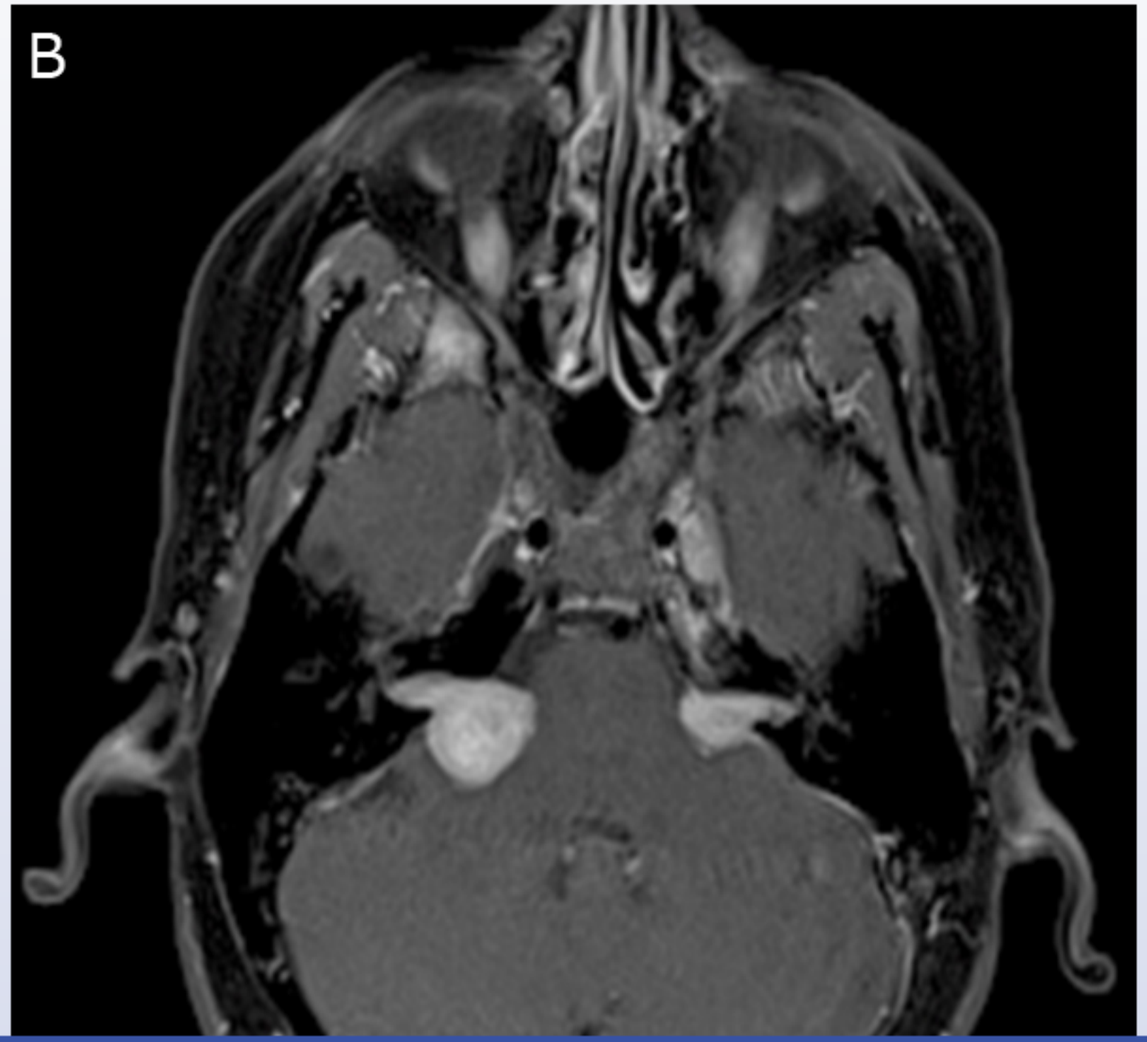

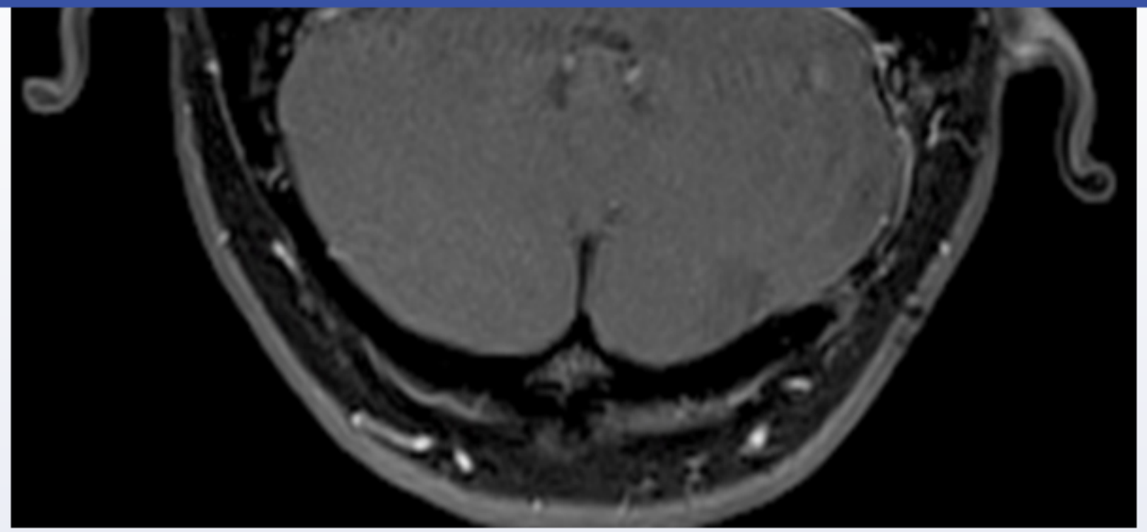

This patient's condition is most likely associated with a mutation involving which of the following genes?

- A. APC on chromosome 5
- B. NF1 on chromosome 17
- C. NF2 on chromosome 22
- D. p53 on chromosome 17
- E. RB1 on chromosome 13
- F. VHL on chromosome 3

Submit

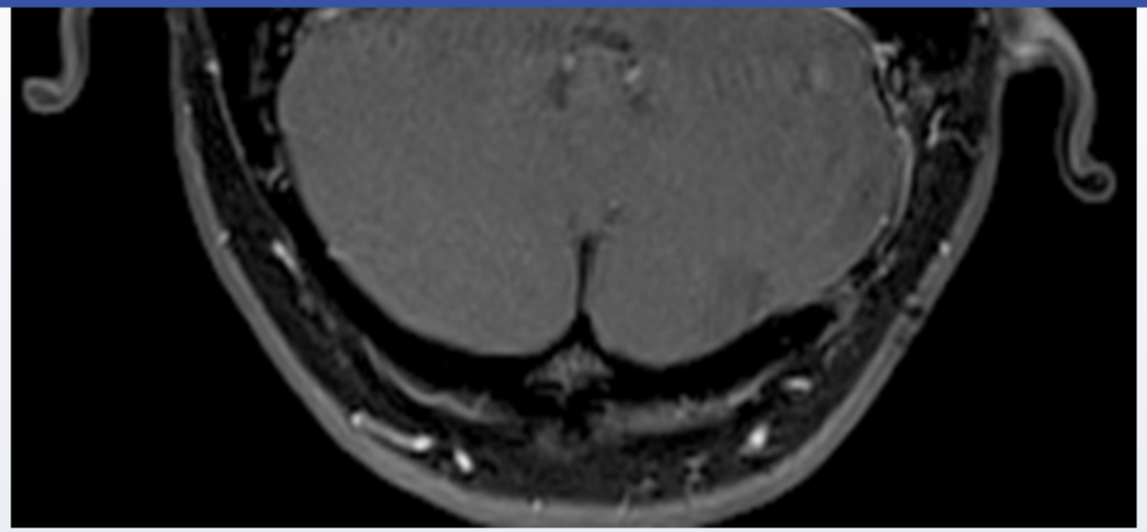

This patient's condition is most likely associated with a mutation involving which of the following genes?

- A. APC on chromosome 5 (0%)
- B. NF1 on chromosome 17 (8%)
- ✓ C. NF2 on chromosome 22 (84%)
- D. p53 on chromosome 17 (1%)
- E. RB1 on chromosome 13 (1%)
- F. VHL on chromosome 3 (3%)

Omitted
Correct answer

84%
Answered correctly

03 secs
Time Spent

04/23/2020
Last Updated

1
2
3
4
5
6
7
8
9
10
11
12
13
14
15
16
17
18
19

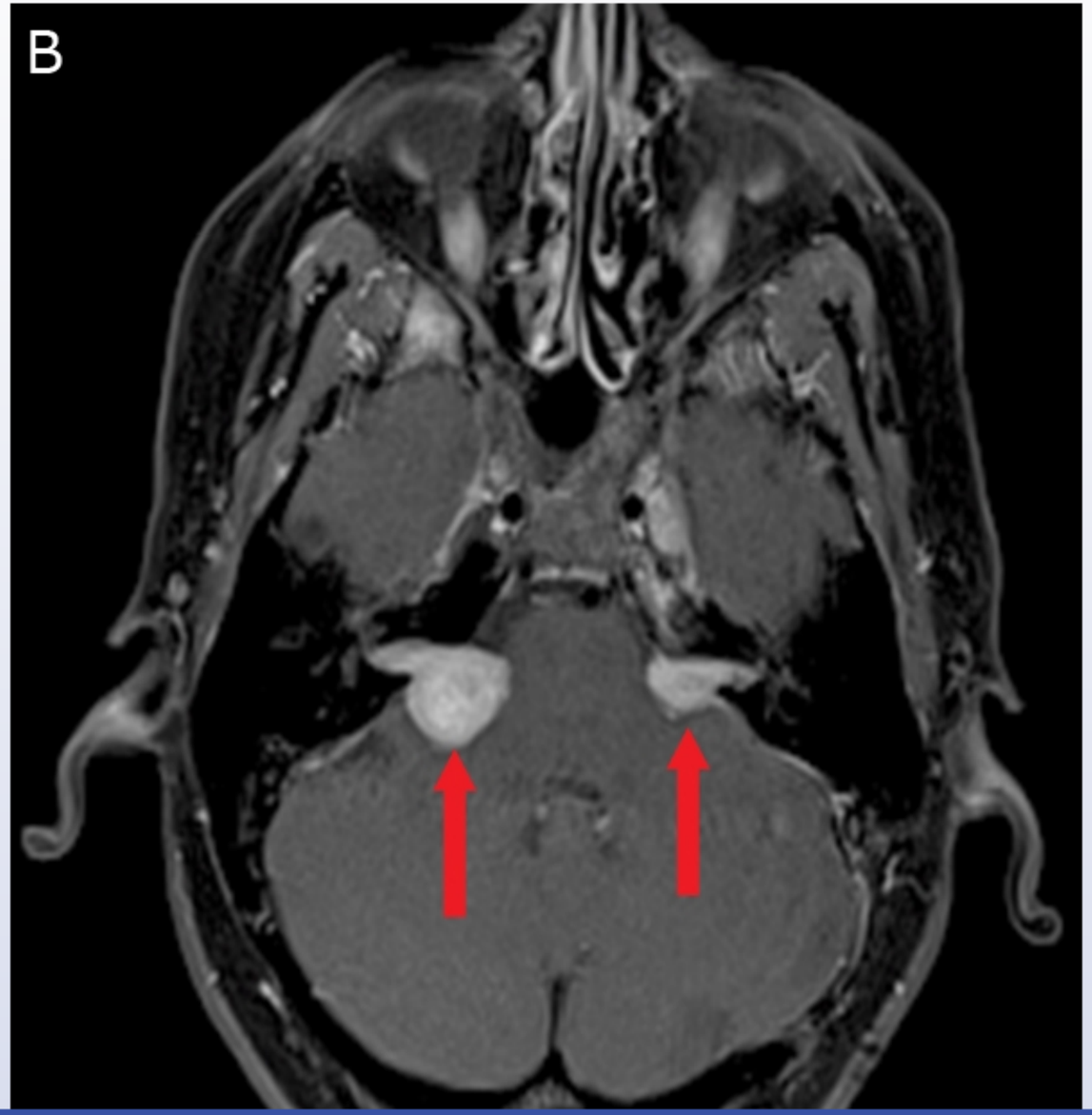

The MRI image above shows bilateral tumors at the cerebellopontine angle (arrows). Most intracranial schwannomas are found at the cerebellopontine angle and are attached to CN VIII. Schwannomas at this location are called acoustic neuromas. Tinnitus, vertigo, and hearing loss are the typical symptoms of an acoustic neuroma. Bilateral acoustic neuromas occur in neurofibromatosis (NF) type 2. NF-2 differs from NF-1 in that it causes fewer cutaneous manifestations and presents with central nervous system involvement.

Both types of neurofibromatosis are **autosomal dominant** conditions, although they occur due to mutations on different chromosomes. The difference between these 2 diseases is summarized below.

Neurofibromatosis types 1 & 2		
Diagnosis	NF1 (von Recklinghausen disease)	NF2 (central neurofibromatosis)
Gene mutation	*NF1* tumor suppressor gene; codes the protein **neurofibromin**	*NF2* tumor suppressor gene; codes the protein **merlin**
Location of mutated gene	Chromosome 17	Chromosome 22
Main clinical features	• Café-au-lait spots • Multiple neurofibromas • Lisch nodules	• Bilateral acoustic neuromas

(Choice A) Mutation of the APC gene (adenomatous polyposis coli) on chromosome 5 is associated with familial adenomatous polyposis syndromes and colon cancer.

(Choice B) Mutation of the NF-1 gene on chromosome 17 leads to NF-1. It is characterized by café-au-lait spots, Lisch nodules, and multiple neurofibromas. Bilateral acoustic neuromas are not characteristic of NF-1.

(Choice D) Mutation of p53 (the tumor suppressor gene on chromosome 17) is the most common mutation found in human cancers. It is also associated with Li-Fraumeni syndrome, a rare familial syndrome characterized by the development of breast cancer, sarcomas, brain tumors, leukemia, and adrenocortical tumors at a young age.

Location of mutated gene	Chromosome 17	Chromosome 22
Main clinical features	• Café-au-lait spots • Multiple neurofibromas • Lisch nodules	• Bilateral acoustic neuromas

(Choice A) Mutation of the APC gene (adenomatous polyposis coli) on chromosome 5 is associated with familial adenomatous polyposis syndromes and colon cancer.

(Choice B) Mutation of the NF-1 gene on chromosome 17 leads to NF-1. It is characterized by café-au-lait spots, Lisch nodules, and multiple neurofibromas. Bilateral acoustic neuromas are not characteristic of NF-1.

(Choice D) Mutation of p53 (the tumor suppressor gene on chromosome 17) is the most common mutation found in human cancers. It is also associated with Li-Fraumeni syndrome, a rare familial syndrome characterized by the development of breast cancer, sarcomas, brain tumors, leukemia, and adrenocortical tumors at a young age.

(Choice E) Mutation of the RB1 tumor suppressor gene on chromosome 13 increases the risk of retinoblastoma and osteosarcoma.

(Choice F) Mutation of the VHL gene on chromosome 3 occurs in von Hippel-Lindau disease. It is characterized by renal cysts, renal cell carcinomas, and hemangioblastomas of the cerebellum and retina.

Educational objective:
Bilateral acoustic neuromas are associated with neurofibromatosis type 2, an autosomal dominant condition caused by mutation of the NF-2 gene on chromosome 22.

Pathology	Nervous System	Neurofibromatosis
Subject	System	Topic

Copyright © UWorld. All rights reserved.

A 26-year-old woman is brought to the emergency department due to acute-onset diplopia. Medical history is significant for episodes of blurry vision involving her right eye that occurred 6 months and 2 years ago. These episodes were associated with deficits in color vision and pain made worse with eye movement. The patient recovered the majority of her visual acuity after a few months in both cases. On neurologic examination, she has a visual acuity of 20/20 OS and 20/40 OD, mild right optic disk atrophy, and a relative afferent pupillary defect in the right eye. There is slowed and impaired adduction of the left eye with right lateral gaze. Convergence testing shows normal adduction in both eyes. The remainder of the neurologic examination is unremarkable. This patient's diplopia is most likely caused by which of the following mechanisms?

A. Impaired neuromuscular transmission

B. Loss of axons

C. Muscle fiber inflammation and necrosis

D. Nerve compression

E. Reduced saltatory conduction

Submit

A 26-year-old woman is brought to the emergency department due to acute-onset diplopia. Medical history is significant for episodes of blurry vision involving her right eye that occurred 6 months and 2 years ago. These episodes were associated with deficits in color vision and pain made worse with eye movement. The patient recovered the majority of her visual acuity after a few months in both cases. On neurologic examination, she has a visual acuity of 20/20 OS and 20/40 OD, mild right optic disk atrophy, and a relative afferent pupillary defect in the right eye. There is slowed and impaired adduction of the left eye with right lateral gaze. Convergence testing shows normal adduction in both eyes. The remainder of the neurologic examination is unremarkable. This patient's diplopia is most likely caused by which of the following mechanisms?

- A. Impaired neuromuscular transmission (8%)
- B. Loss of axons (10%)
- C. Muscle fiber inflammation and necrosis (4%)
- D. Nerve compression (8%)
- ✓ E. Reduced saltatory conduction (67%)

Omitted
Correct answer
E

67%
Answered correctly

01 sec
Time Spent

02/28/2020
Last Updated

Explanation

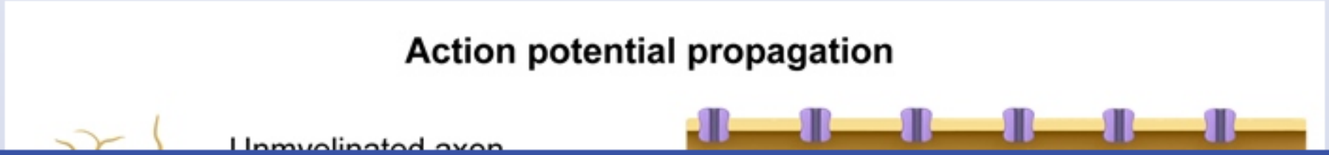

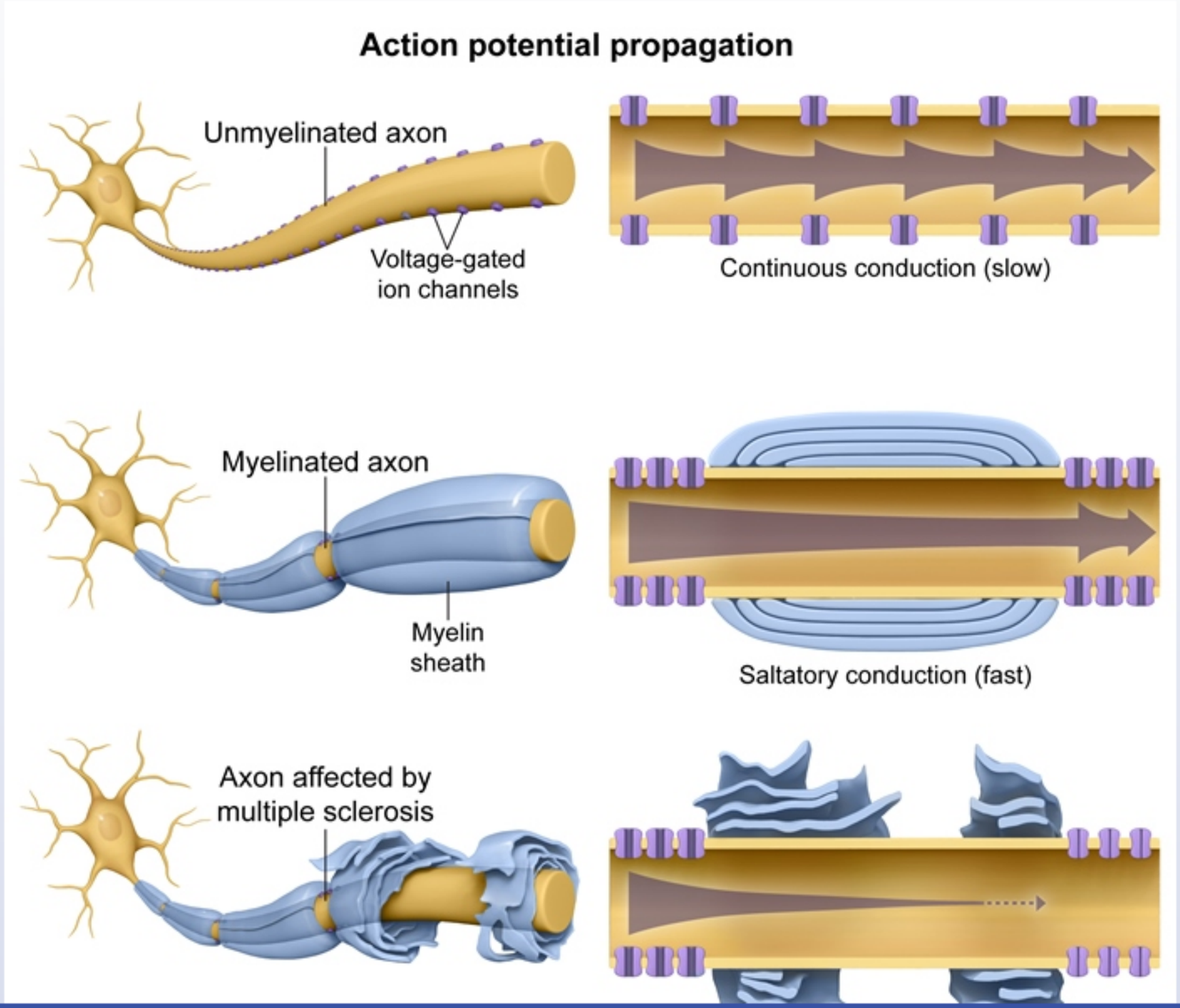
Action potential propagation
Unmyelinated axon
Voltage-gated ion channels
Continuous conduction (slow)
Myelinated axon
Myelin sheath
Saltatory conduction (fast)
Axon affected by multiple sclerosis

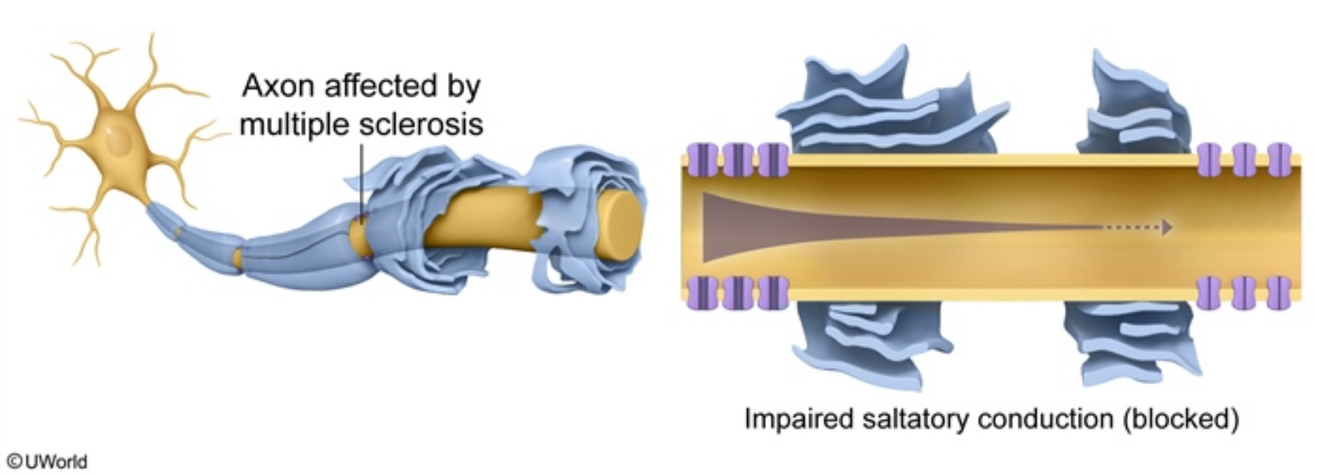

This young woman has diplopia with features of internuclear ophthalmoplegia (impaired adduction on the left with right lateral gaze). This, along with her prior episodes of optic neuritis (transient blurred vision and eye pain with movement), raises concern for **multiple sclerosis (MS)**, a demyelinating disease of the central nervous system (CNS) caused by an autoimmune response directed at oligodendrocytes.

In unmyelinated neurons, signal transmission requires sequential activation of adjacent sodium channels down the entire length of the axon. In myelinated neurons, the depolarization impulse is regenerated at discrete points along the axon (nodes of Ranvier) where sodium channels are concentrated. The myelin sheath serves as an electrical insulator that results in the impulse "jumping" between 2 adjacent nodes **(saltatory conduction)**. This process allows for myelinated neurons to transmit impulses >10x faster than unmyelinated neurons.

Due to the **acute demyelination** seen with MS, propagation of the impulse cannot occur, as the distance between the sodium channels at the nodes of Ranvier precludes sequential activation. This causes a **conduction block**. Over time, sodium channels eventually redistribute across the naked axon and surviving oligodendrocytes partially remyelinate neurons, allowing for some restoration of signal transmission (explaining why some of the symptoms and signs of MS resolve to a variable extent).

(Choice A) Impaired neuromuscular transmission can be seen in myasthenia gravis, which is caused by autoantibodies against acetylcholine receptors at the neuromuscular junction. Affected patients typically present with fluctuating diplopia, ptosis, and/or bulbar muscle weakness.

(Choice B) Loss of axons and neurons occurs over time in *chronic* multiple sclerosis plaques. This patient had prior episodes of optic neuritis

©UWorld

This young woman has diplopia with features of internuclear ophthalmoplegia (impaired adduction on the left with right lateral gaze). This, along with her prior episodes of optic neuritis (transient blurred vision and eye pain with movement), raises concern for **multiple sclerosis (MS)**, a demyelinating disease of the central nervous system (CNS) caused by an autoimmune response directed at oligodendrocytes.

In unmyelinated neurons, signal transmission requires sequential activation of adjacent sodium channels down the entire length of the axon. In myelinated neurons, the depolarization impulse is regenerated at discrete points along the axon (nodes of Ranvier) where sodium channels are concentrated. The myelin sheath serves as an electrical insulator that results in the impulse "jumping" between 2 adjacent nodes **(saltatory conduction)**. This process allows for myelinated neurons to transmit impulses >10x faster than unmyelinated neurons.

Due to the **acute demyelination** seen with MS, propagation of the impulse cannot occur, as the distance between the sodium channels at the nodes of Ranvier precludes sequential activation. This causes a **conduction block**. Over time, sodium channels eventually redistribute across the naked axon and surviving oligodendrocytes partially remyelinate neurons, allowing for some restoration of signal transmission (explaining why some of the symptoms and signs of MS resolve to a variable extent).

(Choice A) Impaired neuromuscular transmission can be seen in myasthenia gravis, which is caused by autoantibodies against acetylcholine receptors at the neuromuscular junction. Affected patients typically present with fluctuating diplopia, ptosis, and/or bulbar muscle weakness.

(Choice B) Loss of axons and neurons occurs over time in *chronic* multiple sclerosis plaques. This patient had prior episodes of optic neuritis that have resolved. However, the internuclear ophthalmoplegia is acute and would demonstrate a relative preservation of axons.

(Choice C) Muscle fiber inflammation and necrosis can be seen with various forms of myositis (eg, polymyositis, dermatomyositis, inclusion body myositis). Muscle disorders rarely follow a relapsing-remitting course and are not associated with optic neuritis or internuclear ophthalmoplegia.

(Choice D) Optic nerve compression would most likely result in progressive vision loss. This patient's symptoms are more consistent with a relapsing-remitting disease pattern with lesions affecting multiple nervous system locations.

Educational objective:
Multiple sclerosis is an autoimmune disorder of the central nervous system characterized by recurrent episodes of demyelination, leading to reduced saltatory conduction. Internuclear ophthalmoplegia and optic neuritis are common manifestations.

©UWorld

Exhibit Display

Gaze palsy with left internuclear ophthalmoplegia

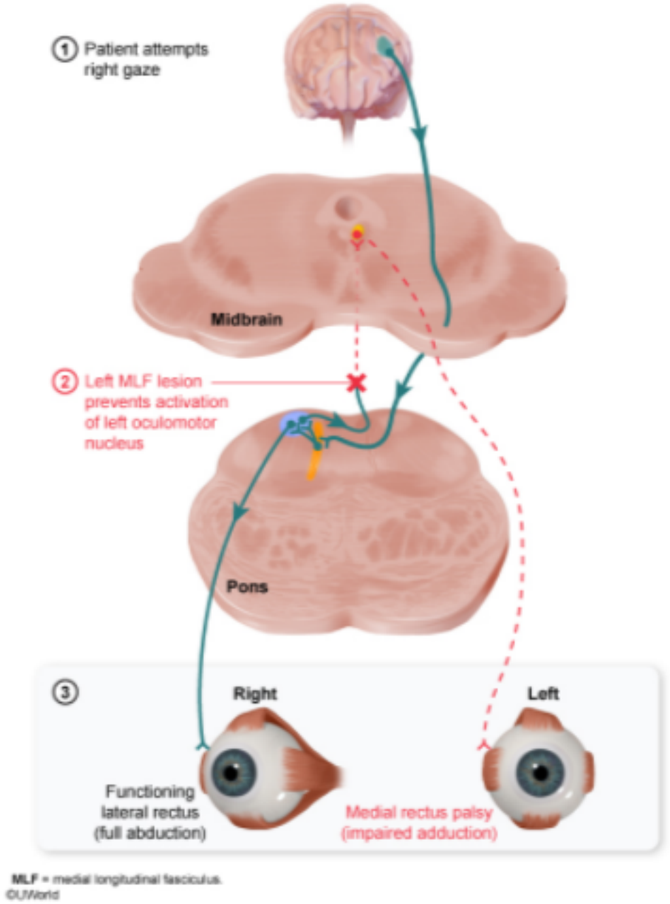

MLF = medial longitudinal fasciculus.
©UWorld

Zoom In | Zoom Out | Reset | Add To New Card | Existing Card

A male neonate is born prematurely to 22-year-old primigravida and experiences severe respiratory distress. The distress resolves with treatment, and by two weeks of age, the patient has adequate respiratory function. Ophthalmoscopy later shows abnormal retinal vascularization that extends into the vitreous. The retinal findings in this patient are most likely related to:

A. Maternal terbutaline treatment

B. Maternal corticosteroid therapy

C. Neonatal antibiotic treatment

D. Neonatal oxygen supplementation

E. Neonatal surfactant supplementation

Submit

A male neonate is born prematurely to 22-year-old primigravida and experiences severe respiratory distress. The distress resolves with treatment, and by two weeks of age, the patient has adequate respiratory function. Ophthalmoscopy later shows abnormal retinal vascularization that extends into the vitreous. The retinal findings in this patient are most likely related to:

A. Maternal terbutaline treatment (2%)

B. Maternal corticosteroid therapy (9%)

C. Neonatal antibiotic treatment (2%)

✓ D. Neonatal oxygen supplementation (76%)

E. Neonatal surfactant supplementation (8%)

Omitted
Correct answer
D

76%
Answered correctly

02 secs
Time Spent

02/03/2020
Last Updated

Explanation

Respiratory distress in a premature neonate is most commonly due to pulmonary surfactant deficiency resulting in hyaline membrane disease. Treatment involves administration of supplemental oxygen at high concentrations, nasal continuous positive airway pressure, and/or mechanical ventilation with intratracheal surfactant. One potential adverse effect of oxygen therapy is retinal damage.

Temporary local hyperoxia in the retina is thought to induce changes that cause up-regulation of proangiogenic factors such as vascular endothelial growth factor (VEGF) upon return to room air ventilation. Retinal vessel proliferation *(neovascularization)* and possible retinal

Explanation

Respiratory distress in a premature neonate is most commonly due to pulmonary surfactant deficiency resulting in hyaline membrane disease. Treatment involves administration of supplemental oxygen at high concentrations, nasal continuous positive airway pressure, and/or mechanical ventilation with intratracheal surfactant. One potential adverse effect of oxygen therapy is retinal damage.

Temporary local hyperoxia in the retina is thought to induce changes that cause up-regulation of proangiogenic factors such as vascular endothelial growth factor (VEGF) upon return to room air ventilation. Retinal vessel proliferation *(neovascularization)* and possible retinal detachment with blindness may result. This complication of neonatal respiratory distress syndrome is referred to as retinopathy of prematurity or retrolental fibroplasia.

(Choice A) Terbutaline is a β-mimetic tocolytic drug used to delay labor and delivery by suppressing uterine contractions. Use of terbutaline has been linked to an increased risk of neonatal intraventricular hemorrhage, hypoglycemia, hypocalcemia, and ileus.

(Choice B) Corticosteroids may be administered to pregnant women entering premature labor in an effort to induce surfactant production by the fetal lungs. Maternal steroid treatment in the prenatal period does not cause neonatal retinal neovascularization.

(Choice C) Neonatal antibiotic treatment does not cause retinal neovascularization.

(Choice E) Complications of surfactant treatment may include transient hypoxia and hypotension, blockage of an endotracheal tube, and pulmonary hemorrhage. Retinal neovascularization is not a known complication.

Educational Objective:
Use of concentrated oxygen therapy for neonatal respiratory distress syndrome may be complicated by retinopathy of prematurity. This abnormal retinal neovascularization is a major cause of blindness in developed nations.

Pathology	Ophthalmology	Neonatal respiratory distress syndrome
Subject	System	Topic

Copyright © UWorld. All rights reserved.

A 68-year-old woman is evaluated for vision impairment. The patient has a decrease in both distant and near vision and has had occasional floaters. She has had no pain or redness in her eyes, headache, focal weakness, or sensory loss. Medical history is notable for type 2 diabetes mellitus, hypertension, and chronic kidney disease. Blood pressure is 138/84 mm Hg and pulse is 76/min. The pupils are equal and reactive to light bilaterally. Anterior chambers are clear, and there are no opacities of the cornea or lens. Funduscopic examination reveals scattered retinal microaneurysms, dot-and-blot hemorrhages, and cotton-wool spots, as well as new blood vessel formation. Which of the following contributed most to the pathogenesis of this patient's current ocular condition?

A. Age-related degeneration of retinal pigment epithelium

B. Chronic hyperglycemia-induced microvascular injury

C. Ganglion cell death due to high intraocular pressure

D. Retinal arterial occlusion from atherosclerotic disease

E. Vascular injury from increased intraluminal pressure

Submit

A 68-year-old woman is evaluated for vision impairment. The patient has a decrease in both distant and near vision and has had occasional floaters. She has had no pain or redness in her eyes, headache, focal weakness, or sensory loss. Medical history is notable for type 2 diabetes mellitus, hypertension, and chronic kidney disease. Blood pressure is 138/84 mm Hg and pulse is 76/min. The pupils are equal and reactive to light bilaterally. Anterior chambers are clear, and there are no opacities of the cornea or lens. Funduscopic examination reveals scattered retinal microaneurysms, dot-and-blot hemorrhages, and cotton-wool spots, as well as new blood vessel formation. Which of the following contributed most to the pathogenesis of this patient's current ocular condition?

- A. Age-related degeneration of retinal pigment epithelium (3%)
- ✓ B. Chronic hyperglycemia-induced microvascular injury (72%)
- C. Ganglion cell death due to high intraocular pressure (0%)
- D. Retinal arterial occlusion from atherosclerotic disease (6%)
- E. Vascular injury from increased intraluminal pressure (16%)

Omitted
Correct answer
B

72%
Answered correctly

01 sec
Time Spent

02/17/2020
Last Updated

Explanation

Diabetic retinopathy, proliferative (PDR)

Diabetic retinopathy, proliferative (PDR)

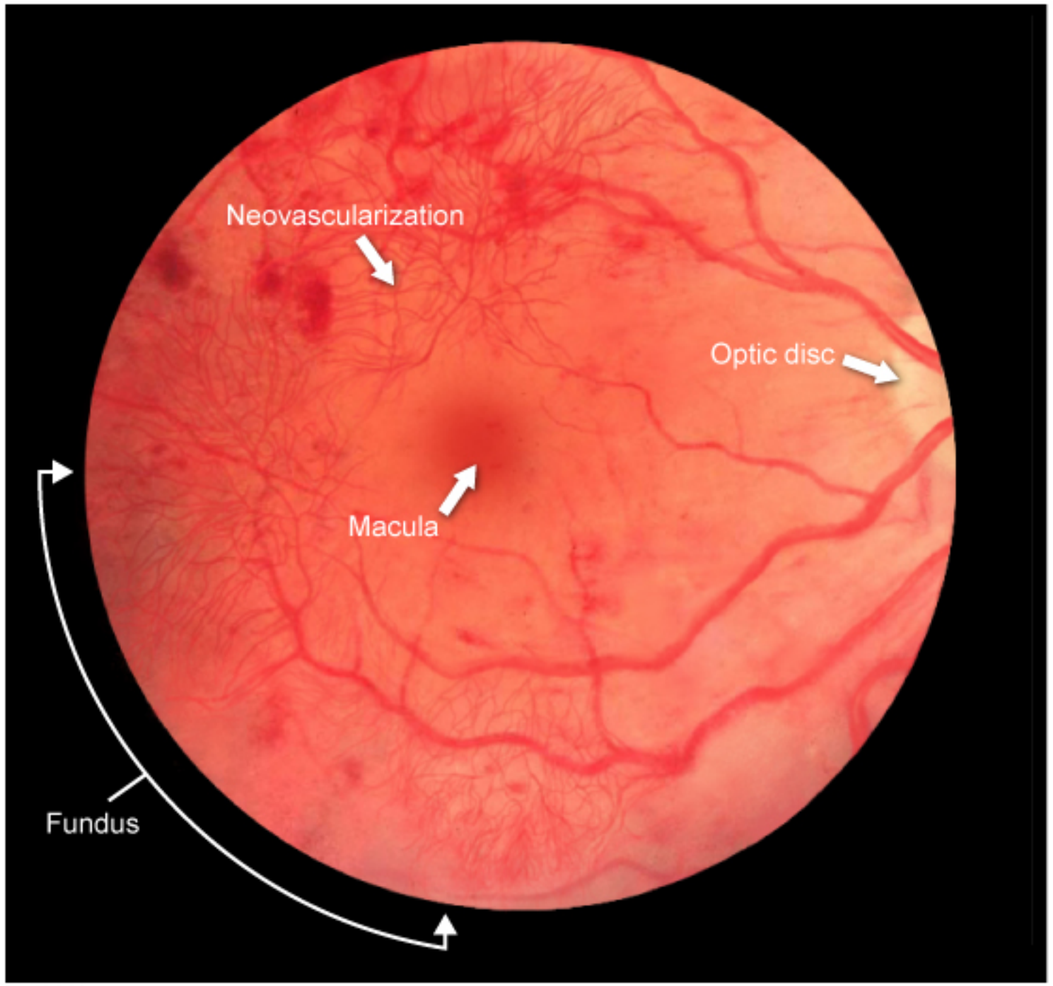

©UWorld

This patient, with painless vision loss and retinal neovascularization, has proliferative **diabetic retinopathy** (DR). DR is a result of chronic hyperglycemic injury to the small retinal vessels and is considered a **microangiopathic** complication of diabetes (along with neuropathy and

©UWorld

This patient, with painless vision loss and retinal neovascularization, has proliferative **diabetic retinopathy** (DR). DR is a result of chronic hyperglycemic injury to the small retinal vessels and is considered a **microangiopathic** complication of diabetes (along with neuropathy and nephropathy). The prevalence of DR is proportionate to the duration of diabetes and severity of hyperglycemia over time; tight control of diabetes is associated with a lower long-term risk of DR.

DR is categorized as follows:

- **Nonproliferative** (early disease): The earliest morphologic changes include thickening of the basement membrane and failure of the blood-retinal barrier. Increased permeability allows leakage of fluid into the retina (macular edema), which can distort vision and leave behind lipid-rich deposits (hard exudates). Arteriolar obstruction causes ischemic injury to the retina, which manifests as cotton-wool spots. Other findings include microaneurysms and dot-blot hemorrhages (due to microaneurysm rupture).
- **Proliferative** (advanced disease): Progressive retinal ischemia stimulates production of angiogenic factors (eg, vascular endothelial growth factor), leading to formation of new retinal vessels (**neovascularization**). The new vessels are fragile and often extend into the adjacent vitreous. Traction from the vitreous can cause detachment of the retina or laceration of the vessels, leading to acute hemorrhage and vision loss.

(Choice A) Age-related macular degeneration presents with slowly progressive *central vision* loss. It is due to oxidative damage to the pigment epithelium and choriocapillaris with abnormal extracellular matrix formation (drusen). In late-stage disease, patients may develop neovascularization ("wet" macular degeneration), but associated findings include subretinal drusen and pigment abnormalities.

(Choice C) Open-angle glaucoma is a form of optic neuropathy, characterized by ganglion cell death in association with elevated intraocular pressure. It causes insidious loss of *peripheral vision*; examination findings include enlargement of the retinal cup and a pale optic disc with thinning of the rim.

(Choice D) Atheroembolic retinal artery occlusion presents with acute *monocular* vision loss. Examination findings include retinal pallor and a cherry red spot at the macula.

(Choice E) Hypertensive retinopathy can manifest with retinal hemorrhages, cotton-wool spots, and hard exudates. However, the thickened and stiffened arterial walls are typically visible as arteriolar narrowing and impingement on the veins where they are crossed by arteries (arteriovenous

lipid-rich deposits (hard exudates). Arteriolar obstruction causes ischemic injury to the retina, which manifests as cotton-wool spots. Other findings include microaneurysms and dot-blot hemorrhages (due to microaneurysm rupture).

- **Proliferative** (advanced disease): Progressive retinal ischemia stimulates production of angiogenic factors (eg, vascular endothelial growth factor), leading to formation of new retinal vessels (**neovascularization**). The new vessels are fragile and often extend into the adjacent vitreous. Traction from the vitreous can cause detachment of the retina or laceration of the vessels, leading to acute hemorrhage and vision loss.

(Choice A) Age-related macular degeneration presents with slowly progressive *central vision* loss. It is due to oxidative damage to the pigment epithelium and choriocapillaris with abnormal extracellular matrix formation (drusen). In late-stage disease, patients may develop neovascularization ("wet" macular degeneration), but associated findings include subretinal drusen and pigment abnormalities.

(Choice C) Open-angle glaucoma is a form of optic neuropathy, characterized by ganglion cell death in association with elevated intraocular pressure. It causes insidious loss of *peripheral vision*; examination findings include enlargement of the retinal cup and a pale optic disc with thinning of the rim.

(Choice D) Atheroembolic retinal artery occlusion presents with acute *monocular* vision loss. Examination findings include retinal pallor and a cherry red spot at the macula.

(Choice E) Hypertensive retinopathy can manifest with retinal hemorrhages, cotton-wool spots, and hard exudates. However, the thickened and stiffened arterial walls are typically visible as arteriolar narrowing and impingement on the veins where they are crossed by arteries (arteriovenous nicking).

Educational objective:
Chronic hyperglycemia in patients with diabetes can lead to increased permeability and arteriolar obstruction in retinal vessels. The resulting ischemia stimulates production of vascular endothelial growth factor and other angiogenic factors, leading to neovascularization (proliferative diabetic retinopathy). Complications include retinal hemorrhage, retinal detachment, and vision loss.

Pathology	Ophthalmology	Diabetic retinopathy
Subject	System	Topic

hyperglycemic injury to the small retinal vessels and is considered a **microangiopathic** complication of diabetes (along with neuropathy and

Exhibit Display

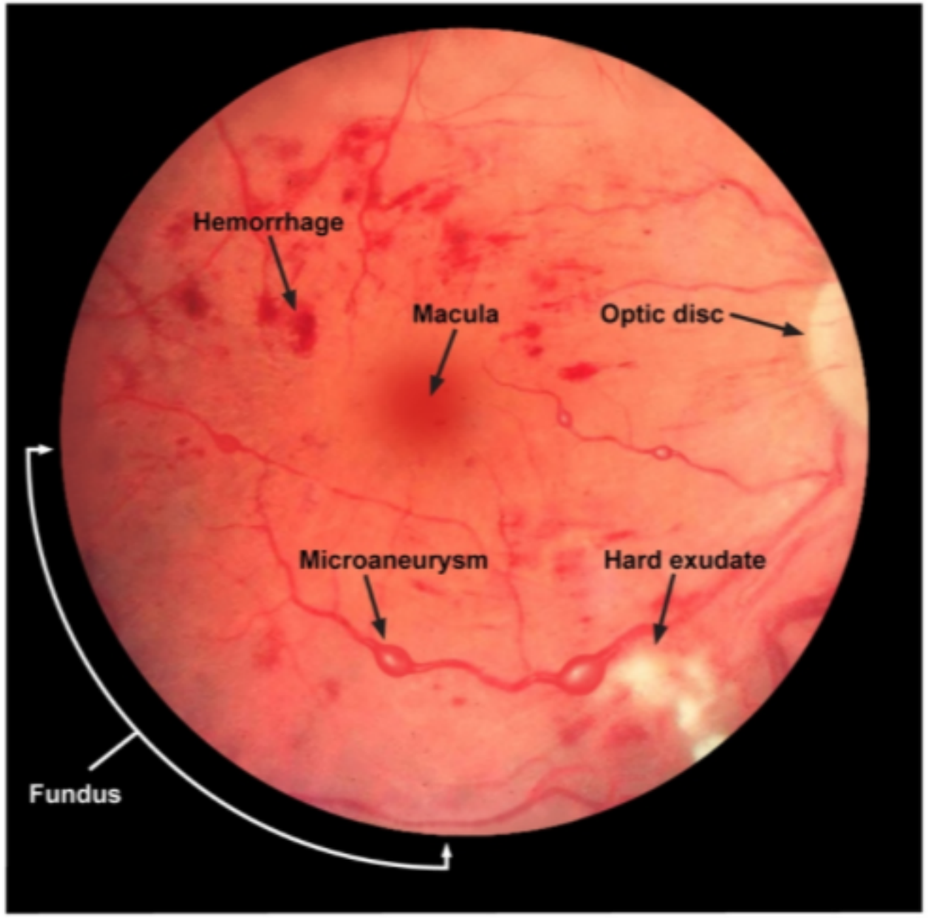

©UWorld

Zoom In | Zoom Out | Reset | Add To New Card | Existing Card

hyperglycemic injury to the small retinal vessels and is considered a **microangiopathic** complication of diabetes (along with neuropathy and

Exhibit Display

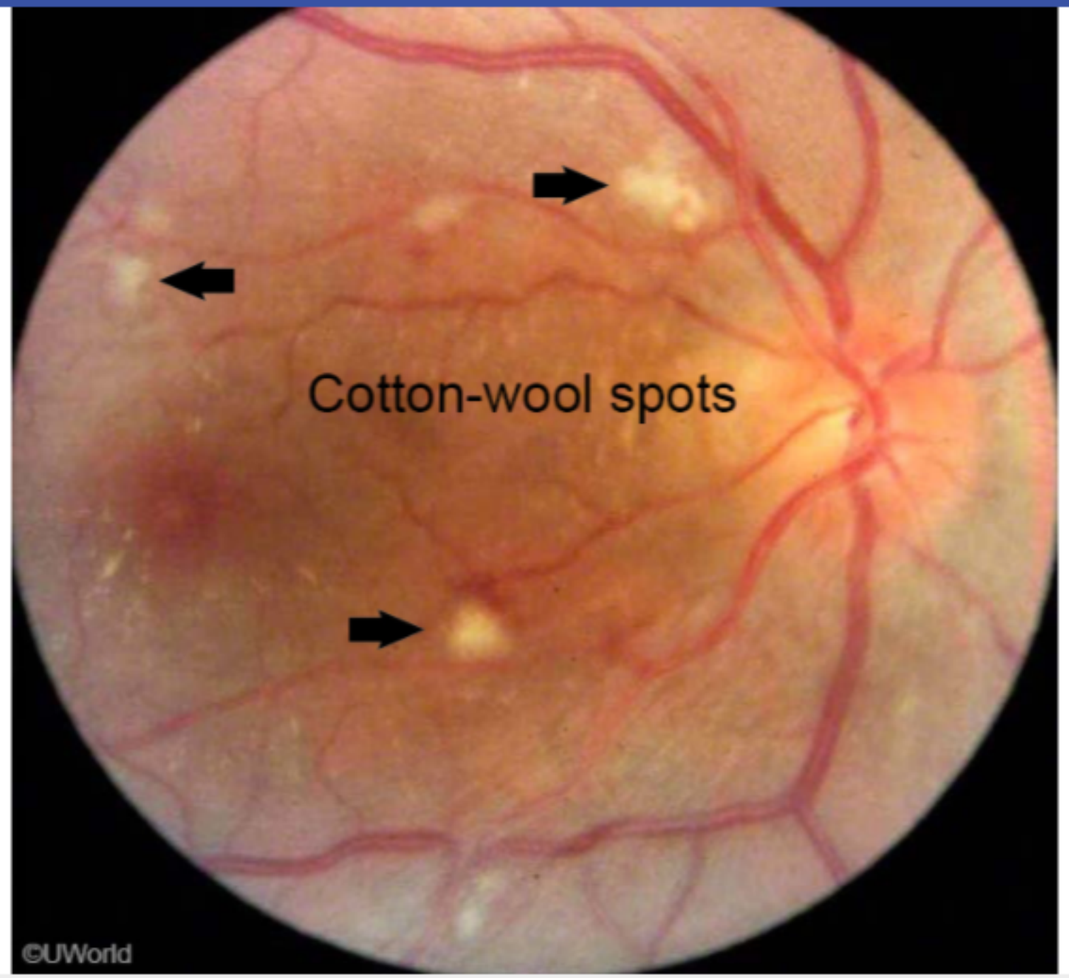

Zoom In | Zoom Out | Reset | Add To New Card | Existing Card

hyperglycemic injury to the small retinal vessels and is considered a **microangiopathic** complication of diabetes (along with neuropathy and

Exhibit Display

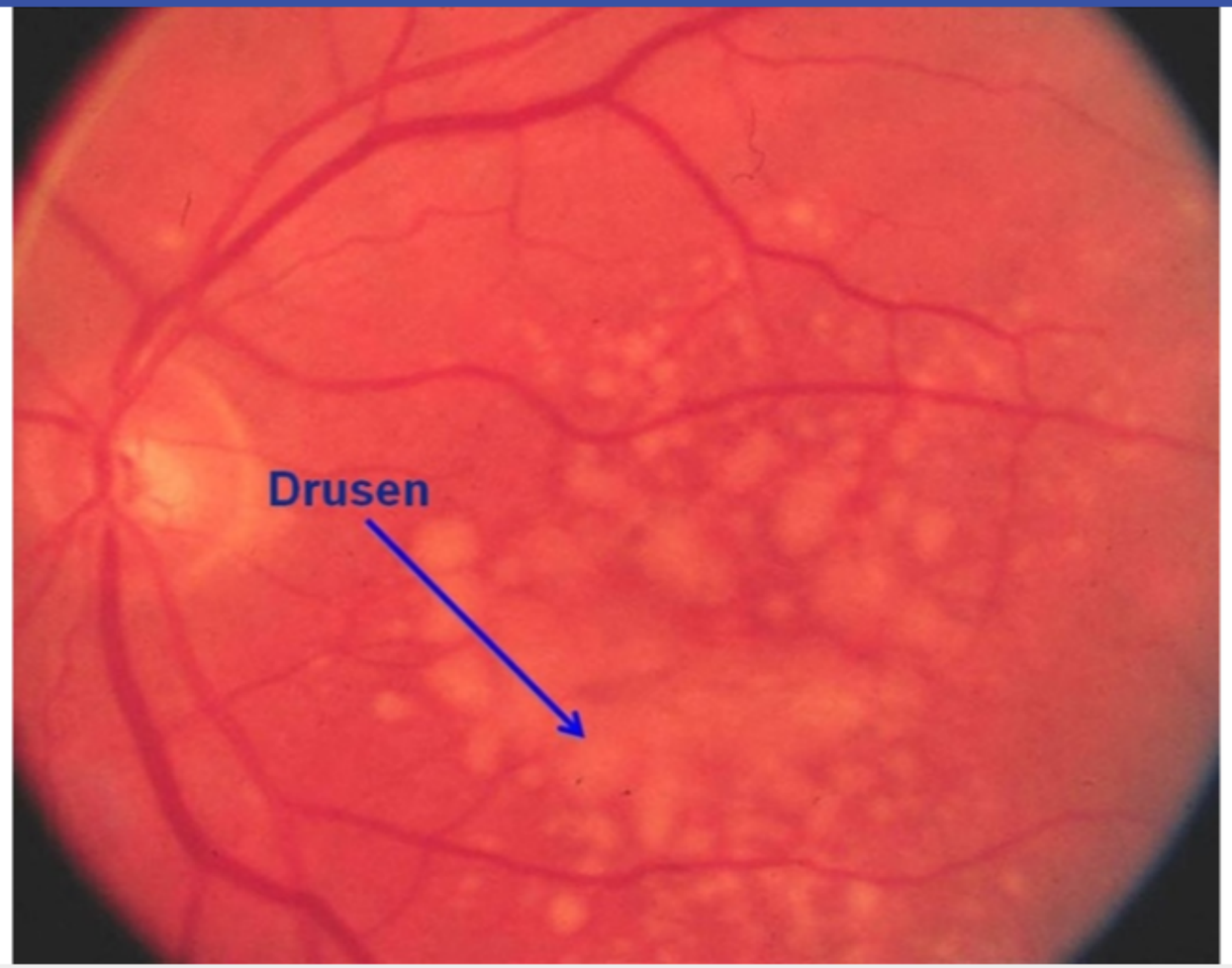

Zoom In | Zoom Out | Reset | Add To New Card | Existing Card

hyperglycemic injury to the small retinal vessels and is considered a **microangiopathic** complication of diabetes (along with neuropathy and

Exhibit Display

Optic disc in glaucoma

Normal	Open-angle glaucoma
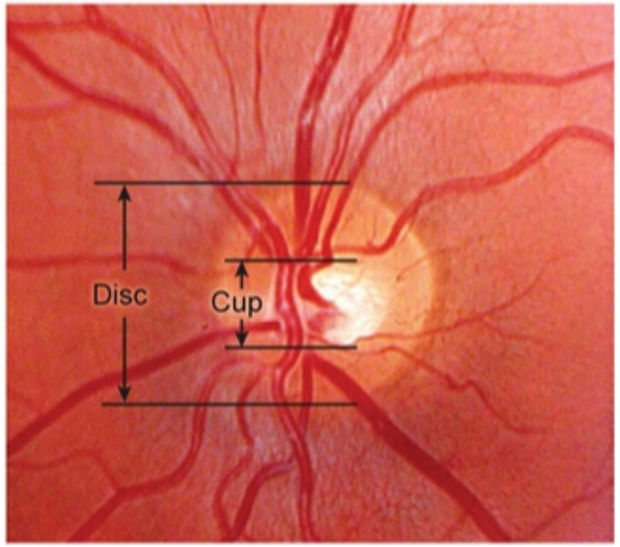	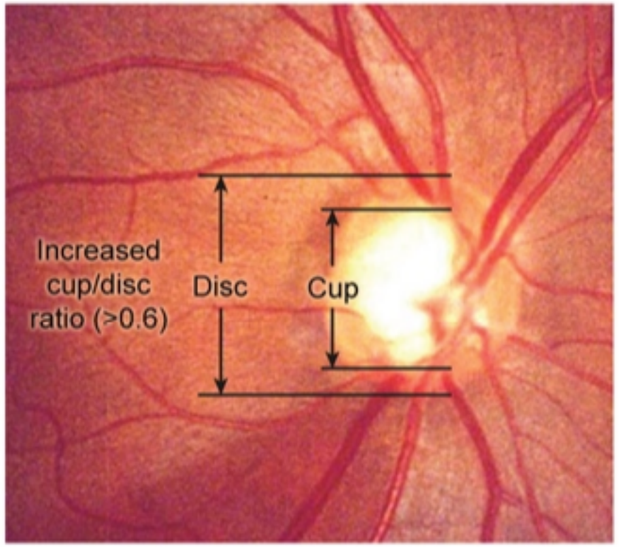
• Cup/disc ratio <0.5 • Clear disc rim	• Enlarged cup with cup/disc ratio >0.6 • Increase in cup size over time • Thinning of disc rim • Pale disc (optic nerve atrophy)

©UWorld

Zoom In | Zoom Out | Reset | Add To New Card | Existing Card

Exhibit Display

Central retinal artery occlusion

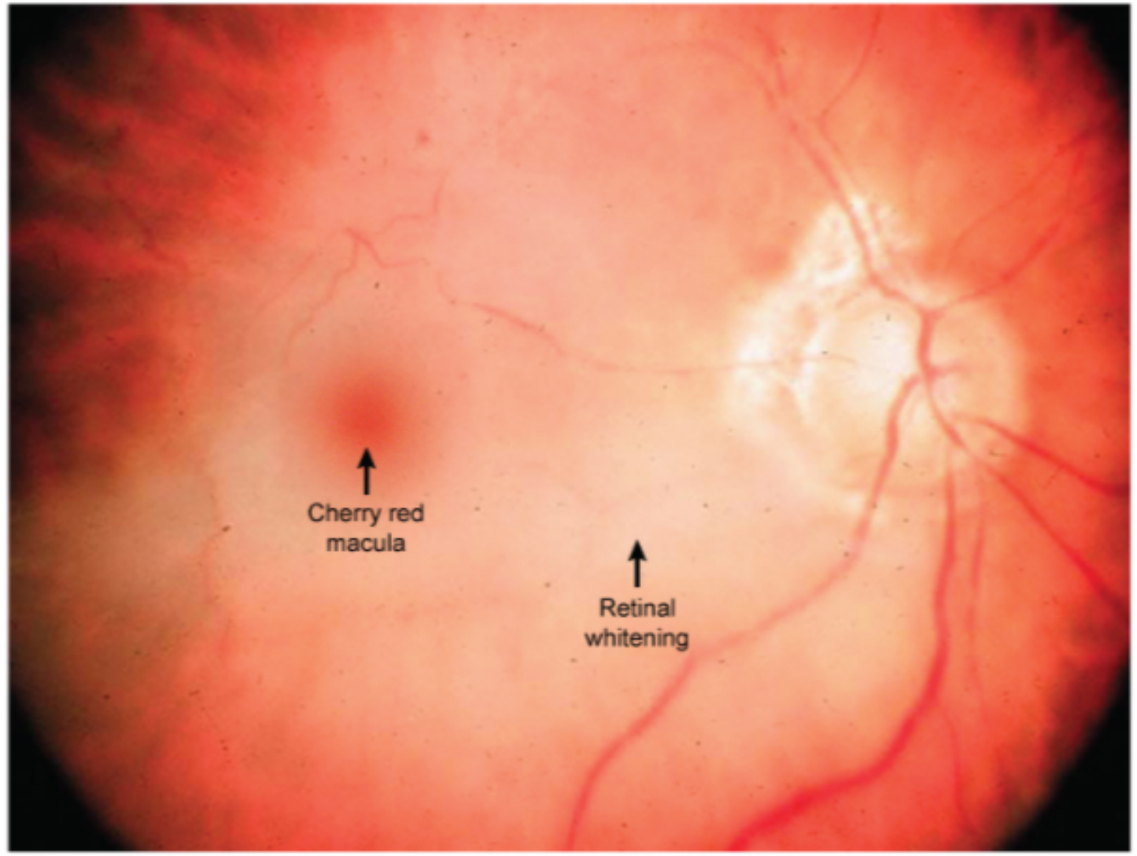

©UWorld

Zoom In Zoom Out Reset Add To New Card | Existing Card

Exhibit Display

Hypertensive retinopathy

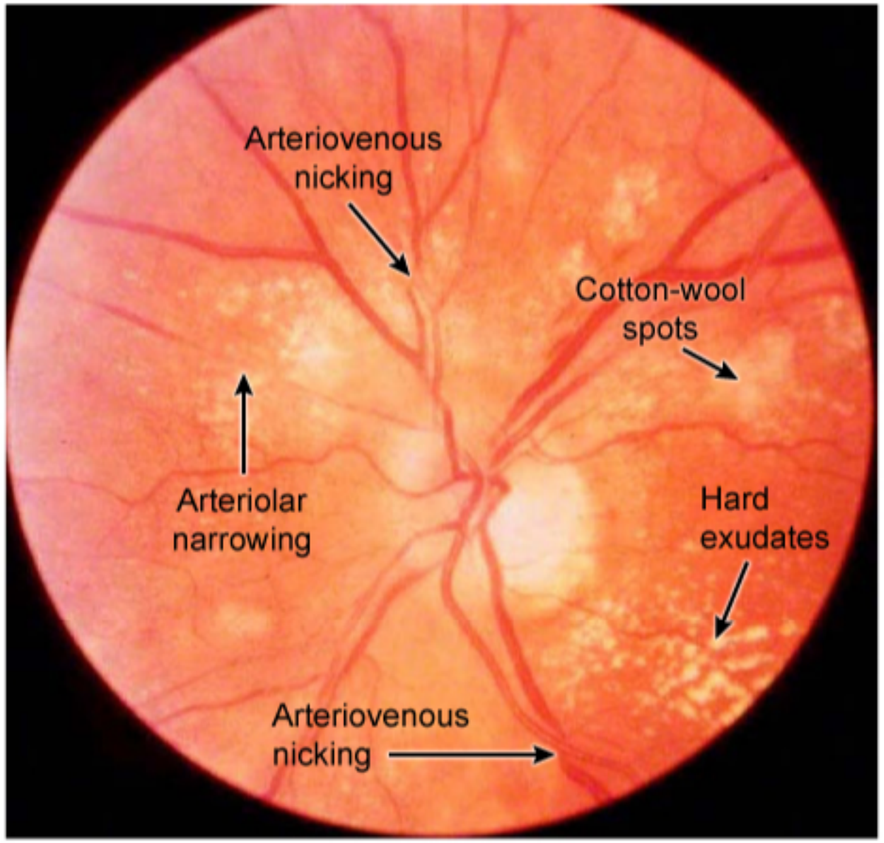

©UWorld

Zoom In | Zoom Out | Reset | Add To New Card | Existing Card

Physical examination of a 23-year-old man diagnosed with chronic hepatitis shows corneal changes that are visible to the naked eye, as shown in the image below.

This patient is most likely to have which of the following conditions?

A. Pulmonary emphysema

B. Diabetes mellitus

This patient is most likely to have which of the following conditions?

- A. Pulmonary emphysema
- B. Diabetes mellitus
- C. Basal ganglia atrophy
- D. Renal cancer
- E. Hypertrophic cardiomyopathy
- F. Congenital deafness

Submit

This patient is most likely to have which of the following conditions?

- A. Pulmonary emphysema (2%)
- B. Diabetes mellitus (14%)
- ✓ C. Basal ganglia atrophy (68%)
- D. Renal cancer (3%)
- E. Hypertrophic cardiomyopathy (7%)
- F. Congenital deafness (3%)

Omitted
Correct answer

68%
Answered correctly

05 secs
Time Spent

04/10/2020
Last Updated

The image demonstrates a Kayser-Fleischer ring, an ophthalmologic finding most strongly associated with Wilson's disease (although it can also be seen in chronic cholestatic diseases such as primary biliary cirrhosis). Kayser-Fleischer rings are best identified on slit-lamp examination, but they can be observed grossly, especially with long-standing, untreated disease. The rings are formed through the granular deposition of copper within Descemet's membrane in the cornea.

Wilson's disease is a rare, autosomal recessive disease most often identified in individuals 5-40 years old. The genetic mutations associated with Wilson's disease hinder copper metabolism by reducing the formation and secretion of ceruloplasmin and decreasing hepatic secretion of copper into the biliary system. Copper is a pro-oxidant and causes damage to hepatic tissue through the generation of free radicals. Eventually, it leaks from injured hepatocytes into the circulation to be deposited in various tissues, including the cornea and basal ganglia. Atrophy of the basal ganglia then ensues.

Treatment is life-long and focuses on removing accumulated copper in the tissues and preventing its re-accumulation. First-line medications include copper chelators such as d-penicillamine and trientine.

(Choice A) Pulmonary emphysema commonly develops in patients with alpha-1 antitrypsin deficiency.

(Choice B) Diabetes mellitus commonly develops in patients with advanced hemochromatosis. It has no association with Wilson's disease.

(Choice D) Renal cancer (clear cell carcinoma) occurs more frequently in patients with von Hippel-Lindau disease, not Wilson's disease.

(Choice E) Hypertrophic cardiomyopathy presenting in childhood and adolescence is an autosomal dominant disease involving the cardiac sarcomere. It is not associated with Wilson's disease.

(Choice F) Congenital deafness can develop secondary to numerous hereditary and nonhereditary conditions. Wilson's disease has no association with congenital deafness.

Educational objective:
The Kayser-Fleischer ring is an ophthalmologic finding most strongly associated with Wilson's disease. It is seen most frequently in patients with neuropsychiatric complications. Basal ganglia atrophy is typically present in these patients.

Pathology Ophthalmology Wilson disease

A 62-year-old man with a history of poor medical follow-up comes to the office due to difficulty seeing. He has had blurry vision for the last 2 weeks. A day ago, he noticed a shadow develop suddenly across the visual field of his right eye. The patient has had no recent headaches, double vision, vertigo, light sensitivity, or nausea. On examination, pupils are equal and reactive to light. Visual field testing by confrontation reveals patchy loss of vision. A flame-shaped retinal hemorrhage in the right eye is noted on funduscopic examination, as shown in the image below.

Which of the following is the most likely cause of his visual disturbance?

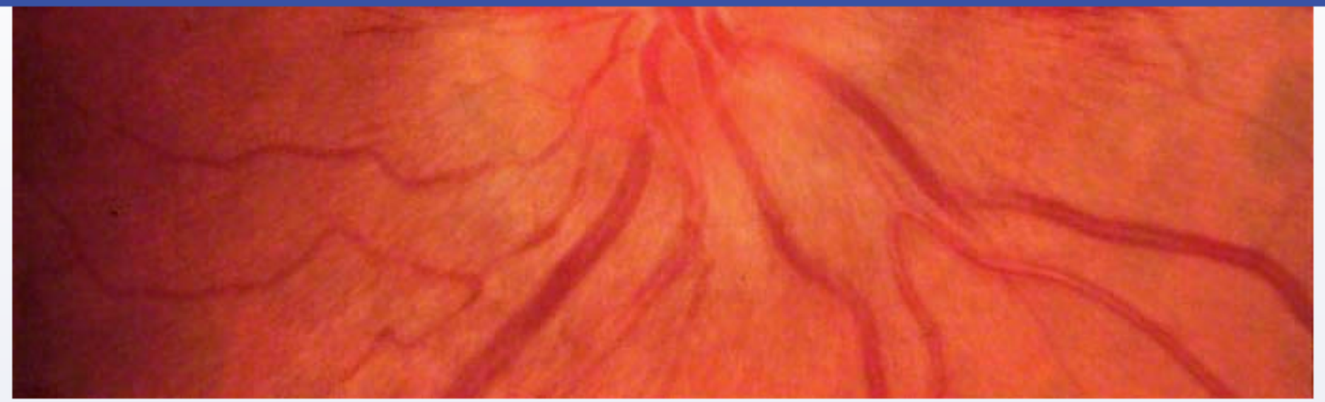

Which of the following is the most likely cause of his visual disturbance?

- A. Central retinal artery occlusion
- B. Cigarette smoking
- C. Closed-angle glaucoma
- D. Giant cell arteritis
- E. Hyperlipidemia
- F. Hypertension
- G. Migraine
- H. Thyroid eye disease

Submit

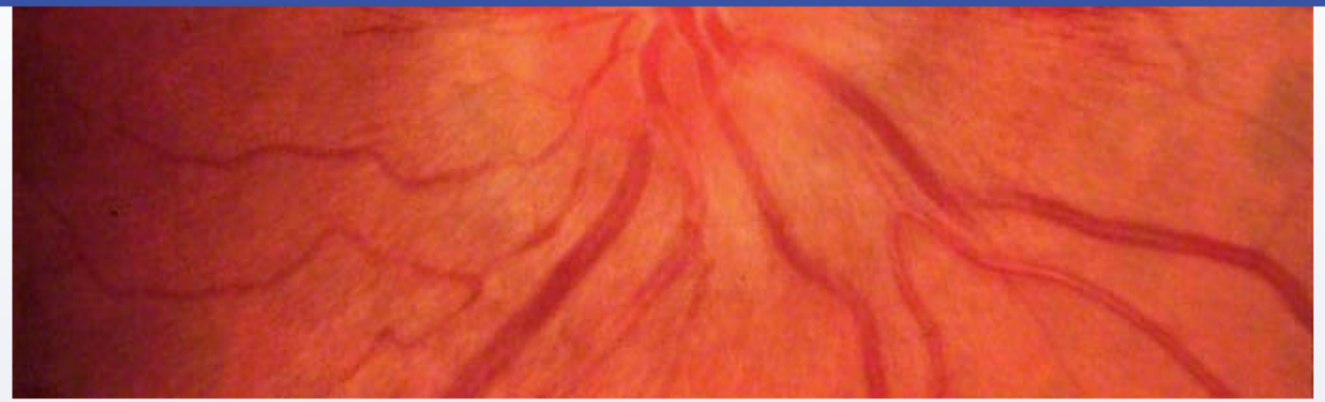

Which of the following is the most likely cause of his visual disturbance?

- A. Central retinal artery occlusion (18%)
- B. Cigarette smoking (4%)
- C. Closed-angle glaucoma (4%)
- D. Giant cell arteritis (3%)
- E. Hyperlipidemia (3%)
- ✓ F. Hypertension (66%)
- G. Migraine (0%)
- H. Thyroid eye disease (0%)

Omitted
Correct answer

66%
Answered correctly

06 secs
Time Spent

05/31/2020
Last Updated

Explanation

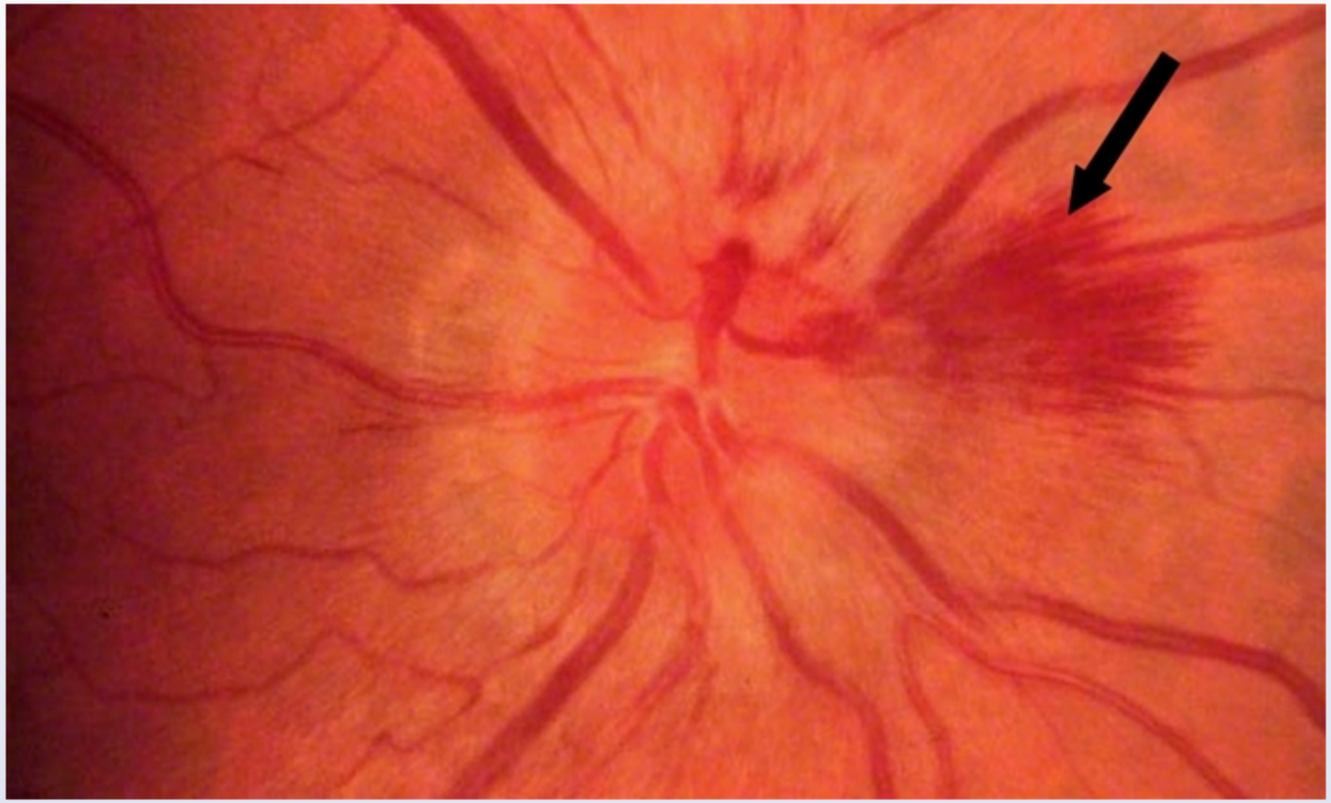

This patient has an acute retinal hemorrhage (arrow), most likely caused by severe, poorly controlled **hypertension**. Hypertensive retinal hemorrhage typically causes painless, unilateral visual disturbances, ranging from mild obscuration without loss of visual acuity to permanent blindness. Severe hypertension in retinal precapillary arterioles causes endothelial disruption, leakage of plasma into the arteriolar wall, and **fibrinous necrosis**. The necrotic vessels can then bleed into the nerve fiber layers, causing dot- and flame-shaped hemorrhages.

Diagnosis of hypertensive retinal hemorrhage is usually confirmed by direct ophthalmoscopic evaluation. Other findings of hypertensive retinopathy include thickening of the arteriolar walls ("copper or silver wiring"), compression of the associated veins (arteriovenous nicking), and

This patient has an acute retinal hemorrhage (arrow), most likely caused by severe, poorly controlled **hypertension**. Hypertensive retinal hemorrhage typically causes painless, unilateral visual disturbances, ranging from mild obscuration without loss of visual acuity to permanent blindness. Severe hypertension in retinal precapillary arterioles causes endothelial disruption, leakage of plasma into the arteriolar wall, and **fibrinous necrosis**. The necrotic vessels can then bleed into the nerve fiber layers, causing dot- and flame-shaped hemorrhages.

Diagnosis of hypertensive retinal hemorrhage is usually confirmed by direct ophthalmoscopic evaluation. Other findings of hypertensive retinopathy include thickening of the arteriolar walls ("copper or silver wiring"), compression of the associated veins (arteriovenous nicking), and small, white foci of retinal ischemia (cotton-wool spots).

(Choices A and D) Central retinal artery occlusion is most commonly due to atherosclerosis, cardioembolic disease, or vasculitis (eg, giant cell arteritis). It causes acute monocular vision loss. Examination can reveal a cherry red spot at the macula due to diffuse retinal ischemia, but hemorrhage is not typically seen.

(Choices B and E) Smoking and hyperlipidemia can increase the risk of developing ischemic retinal and optic vascular disease; however, these are not associated with an increased risk of retinal hemorrhage.

(Choice C) Closed-angle glaucoma is characterized by increased intraocular pressure from impaired aqueous humor drainage. It causes acute headache, eye pain, vision loss, and an afferent pupillary defect. Ophthalmoscopic examination reveals cupping of the optic disc without hemorrhage.

(Choice G) Ocular migraine and migraine with visual aura can present with transient visual disturbances, with or without headache. Ophthalmoscopic examination is normal in patients with migraine.

(Choice H) Thyroid eye disease (eg, Graves disease) can present with diplopia and proptosis; however, it is not associated with an increased risk of retinal hemorrhage.

Educational objective:
Severe hypertension in retinal precapillary arterioles causes endothelial disruption, leakage of plasma into the arteriolar wall, and fibrinous necrosis. The necrotic vessels can then bleed into the nerve fiber layer, which can be seen on examination as dot- or flame-shaped hemorrhages.

Pathology Ophthalmology Hypertensive retinopathy

fibrinous necrosis. The necrotic vessels can then bleed into the nerve fiber layers, causing dot- and flame-shaped hemorrhages.

Diagnosis of hypertensive retinal hemorrhage is usually confirmed by direct ophthalmoscopic evaluation. Other findings of hypertensive retinopathy include thickening of the arteriolar walls ("copper or silver wiring"), compression of the associated veins (arteriovenous nicking), and small, white foci of retinal ischemia (cotton-wool spots).

(Choices A and D) Central retinal artery occlusion is most commonly due to atherosclerosis, cardioembolic disease, or vasculitis (eg, giant cell arteritis). It causes acute monocular vision loss. Examination can reveal a cherry red spot at the macula due to diffuse retinal ischemia, but hemorrhage is not typically seen.

(Choices B and E) Smoking and hyperlipidemia can increase the risk of developing ischemic retinal and optic vascular disease; however, these are not associated with an increased risk of retinal hemorrhage.

(Choice C) Closed-angle glaucoma is characterized by increased intraocular pressure from impaired aqueous humor drainage. It causes acute headache, eye pain, vision loss, and an afferent pupillary defect. Ophthalmoscopic examination reveals cupping of the optic disc without hemorrhage.

(Choice G) Ocular migraine and migraine with visual aura can present with transient visual disturbances, with or without headache. Ophthalmoscopic examination is normal in patients with migraine.

(Choice H) Thyroid eye disease (eg, Graves disease) can present with diplopia and proptosis; however, it is not associated with an increased risk of retinal hemorrhage.

Educational objective:
Severe hypertension in retinal precapillary arterioles causes endothelial disruption, leakage of plasma into the arteriolar wall, and fibrinous necrosis. The necrotic vessels can then bleed into the nerve fiber layer, which can be seen on examination as dot- or flame-shaped hemorrhages.

Pathology	Ophthalmology	Hypertensive retinopathy
Subject	System	Topic

Copyright © UWorld. All rights reserved.

Exhibit Display

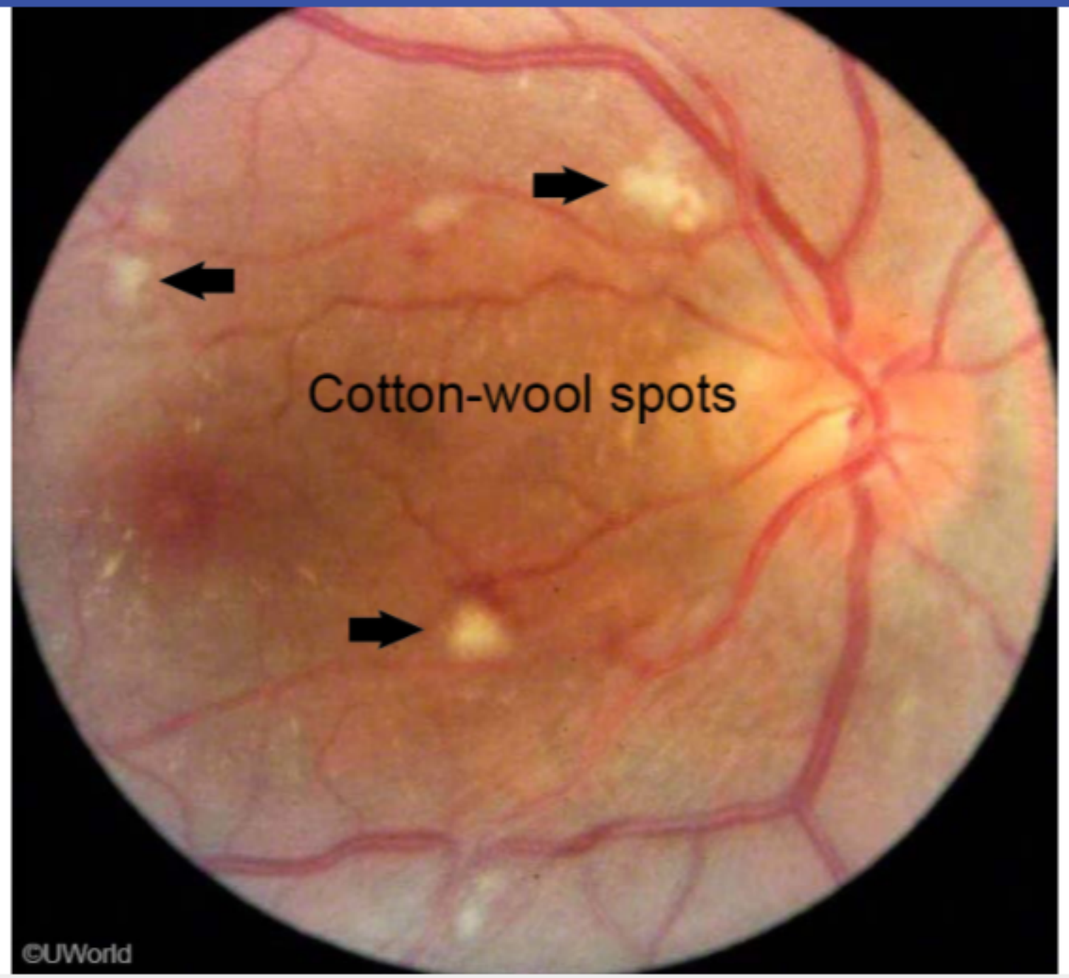

Zoom In | Zoom Out | Reset | Add To New Card | Existing Card

of retinal hemorrhage.

Exhibit Display

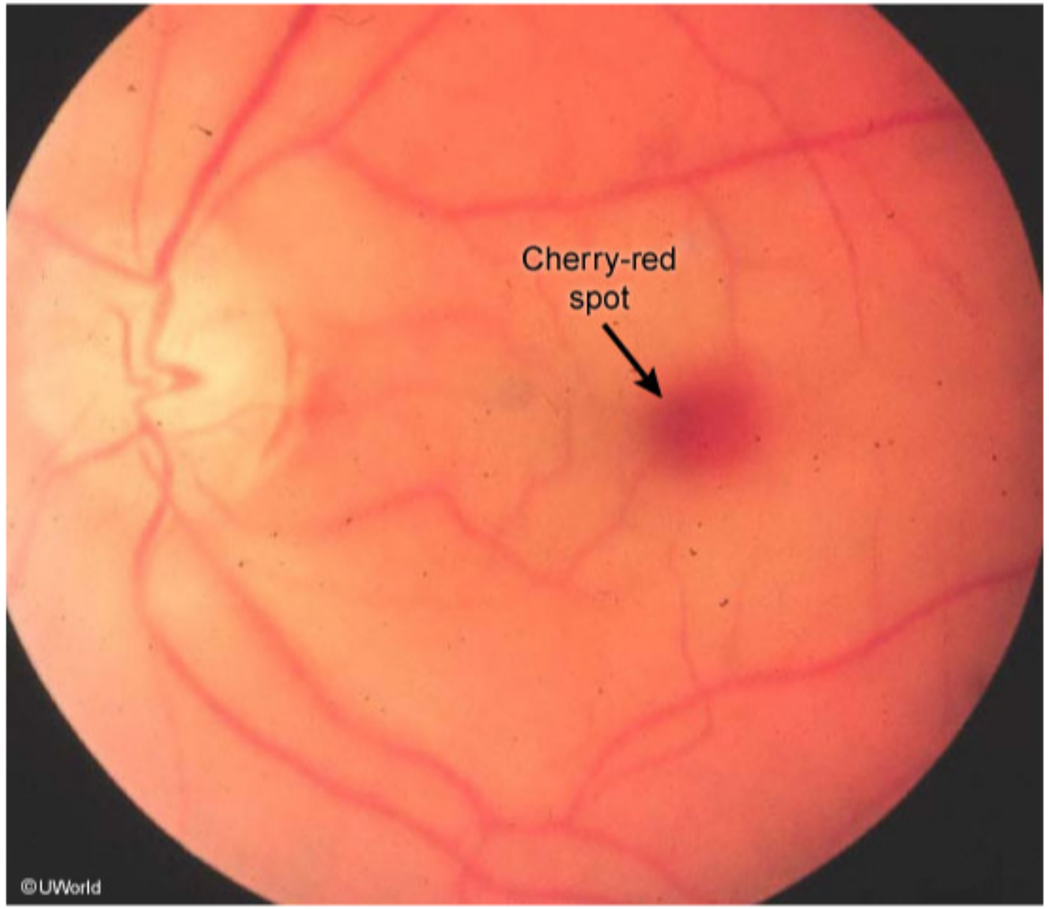

Zoom In | Zoom Out | Reset | Add To New Card | Existing Card

of retinal hemorrhage.

A 3-month-old boy is brought to the office by his mother for a routine checkup. He is found to have a right-sided white pupillary reflex. His father was diagnosed with a retinal neoplasm during childhood and had his left eye enucleated. This child is at the greatest risk of developing which of the following neoplasms?

A. Acute lymphoblastic leukemia
B. Neuroblastoma
C. Ewing sarcoma
D. Osteosarcoma
E. Medulloblastoma

Submit

A 3-month-old boy is brought to the office by his mother for a routine checkup. He is found to have a right-sided white pupillary reflex. His father was diagnosed with a retinal neoplasm during childhood and had his left eye enucleated. This child is at the greatest risk of developing which of the following neoplasms?

A. Acute lymphoblastic leukemia (2%)
B. Neuroblastoma (22%)
C. Ewing sarcoma (5%)
✓ D. Osteosarcoma (62%)
E. Medulloblastoma (6%)

Omitted
Correct answer
D

62%
Answered correctly

03 secs
Time Spent

04/05/2020
Last Updated

Explanation

Knudson's 2-hit hypothesis

Both copies of the gene must be knocked out to promote malignancy.

Sporadic cancer:
2 acquired mutations

Knudson's 2-hit hypothesis

Both copies of the gene must be knocked out to promote malignancy.

Sporadic cancer:
2 acquired mutations

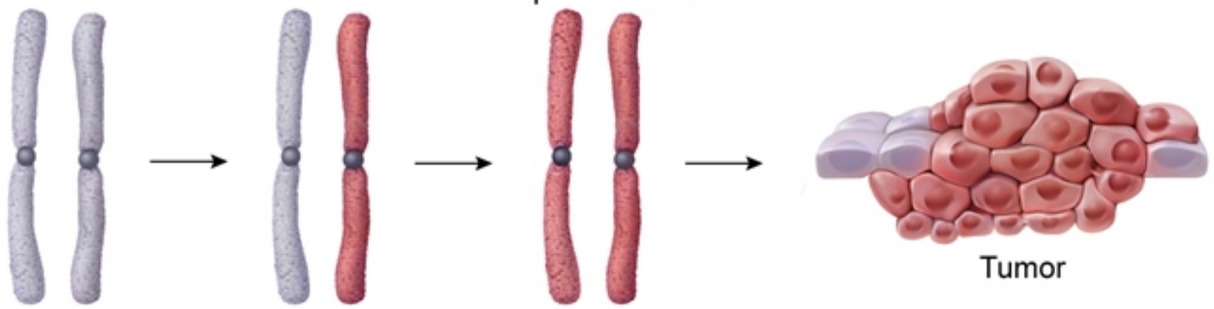

Hereditary cancer:
1 inherited and 1 acuired mutation

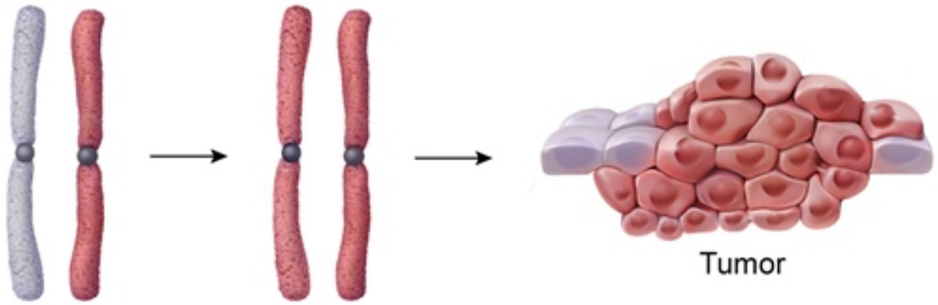

©UWorld

Retinoblastoma is the most common ocular tumor of childhood. It usually presents with a white pupillary reflex (leukocoria) in children <5 years old. Approximately 60% of retinoblastomas are sporadic (usually unilateral), while **40% are familial** (often, but not always, bilateral).

Retinoblastoma is the most common ocular tumor of childhood. It usually presents with a white pupillary reflex (leukocoria) in children <5 years old. Approximately 60% of retinoblastomas are sporadic (usually unilateral), while **40% are familial** (often, but not always, bilateral).

Familial retinoblastoma occurs due to a **germline mutation** that affects the **Rb tumor suppressor gene** on chromosome 13; affected children carry one copy of the mutation in all their cells. However, there are two copies of the Rb gene (one allele from each parent), and malignancy does not occur while at least one copy of the gene is still functional. A somatic second mutation acquired early in life is the "**second hit**" that leads to retinoblastoma, as cells with **two inactivated Rb genes** proliferate uncontrollably and give rise to **malignancy**.

Children with familial retinoblastoma often acquire other "second hit" mutations later in life, leading to additional tumors, usually sarcomas such as **osteosarcoma**. In contrast, patients with sporadic retinoblastoma are not at risk for other malignancies, as the chance of two acquired somatic mutations occuring multiple times in different cell lineages is very low.

(Choice A) Patients with Down syndrome, ataxia-telangiectasia, and neurofibromatosis type 1 have an increased risk of development of acute lymphoblastic leukemia, which is not associated with familial retinoblastoma.

(Choice B) Neuroblastoma is a common childhood cancer that arises from sympathetic nervous tissue, most commonly in the adrenals. Most cases are sporadic.

(Choice C) Ewing sarcoma is an undifferentiated neoplasm of mesenchymal origin that most commonly occurs in the long and flat bones of children and adolescents. It occurs sporadically.

(Choice E) Medulloblastoma is the most common *malignant* brain tumor of childhood, typically arising in the cerebellum.

Educational objective:
Familial retinoblastoma occurs as a result of mutations of each of the two Rb genes ("two hits"). These patients have an increased risk of secondary tumors, especially osteosarcomas, later in life.

Pathology	Ophthalmology	Retinoblastoma
Subject	System	Topic

Copyright © UWorld. All rights reserved.